

# Midfacial Rejuvenation

Brent R. W. Moelleken, M.D., FACS<sup>1</sup>

## ABSTRACT

The midface is an important new area in facial rejuvenation. Rejuvenation of the midface is necessary to achieve harmonious rejuvenation of the face. The extent of "lift" to be achieved with midfacial elevation is very limited. Excessive elevation of midfacial tissues results in vertical shortening of the lower eyelid, round eye deformity, and ectropion. In patients with previous blepharoplasty or midfacelifts, minimal or no tissue can be resected. Instead, any midfacial advancement achieved is required to reconstruct the lower eyelid form and allow a canthoplasty or canthopexy to heal without undue downward traction on the repair. The surgeon must elevate the midface tissue in a very limited, safe fashion. Many current approaches to midfacial rejuvenation exist in a number of anatomic planes, with several fixation techniques. Some surgical approaches, such as surgery in a suborbicularis plane, may be inherently safer than others. Aesthetic micromanagement of the lower eyelid position and orbicularis muscle is possible. A useful test for assessing the amount of available midfacial tissue is provided.

**KEYWORDS:** Midfacial rejuvenation, blepharoplasty, aesthetic micromanagement

It is becoming common for surgeons to offer midfacial rejuvenation in their practices. It is difficult to rationalize not offering such techniques when a thorough knowledge of midfacial and lateral brow anatomy and a familiarity of various midfacial rejuvenation techniques can enhance our ability to rejuvenate the face more harmoniously. Surgeons performing complex lower blepharoplasties, including revisions, surgery on forward set globes, and cases with lower eyelid laxity, must be familiar with midfacial procedures and ectropion repair and reconstruction.

Surgeons who rejuvenate the midface often try to reverse many of the signs of aging and do as little harm in the process. The extent of facial aging covers all layers and anatomic units of the midface. Surgeons can only focally improve some of these aging stigmata. A thorough preoperative consultation can determine which of the many signs of facial aging bother the patient and which are amenable to correction.

Available treatments now include composite grafting for hollow regions, fat preservation in perior-

bital surgery, and an understanding of advancements in lower eyelid and midfacial rejuvenation. Skin care, peels, and lasers can improve and restore the quality of skin and reduce fine rhytids and sun damage.

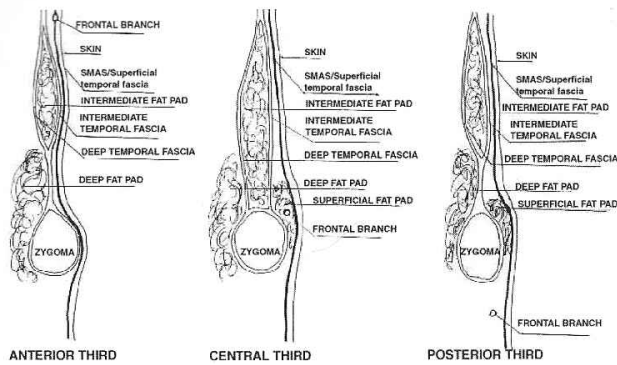
Problems of aging skin surfaces and fat atrophy, specifically, facial and periorbital fat atrophy, buccal fat pad, and malar fat pad as well as global fat atrophy in the subcutaneous tissue, are still unsolved.

## MIDFACIAL ANATOMY

When performing subperiosteal midfacial procedures, careful dissection is necessary to avoid damage to the frontal branch of the facial nerve. The surgeon must break through the intermediate temporal fascia (ITF) into the temporal fat pad space, and from there go into the zygomatic subperiosteal space.

The deep temporal fascia (DTF) forms the floor for the temporal fat pad (Fig. 1). The ITF forms the roof for the temporal fat pad. The ITF is separate from and located deep to the SMAS/superficial temporal fas-

Surgery for Midfacial Rejuvenation; Editors in Chief, Fred Fedok, M.D., Gilbert J. Nolst Trenité, M.D., Ph.D., Daniel G. Becker, M.D., Roberta Gausas, M.D.; Guest Editor, Andrew S. Frankel, M.D., FACS. *Facial Plastic Surgery*, Volume 19, Number 2, 2003. Address for correspondence and reprint requests: Brent R. W. Moelleken, M.D., 120 South Spalding Drive, Suite 340, Beverly Hills, CA 90212. <sup>1</sup>Private Practice, Beverly Hills, CA. Copyright © 2003 by Thieme Medical Publishers, Inc., 333 Seventh Avenue, New York, NY 10001, USA. Tel: +1(212) 584-4662. 0736-6825,p;2003,19,02,209,222,ftx,en;fps00465x.



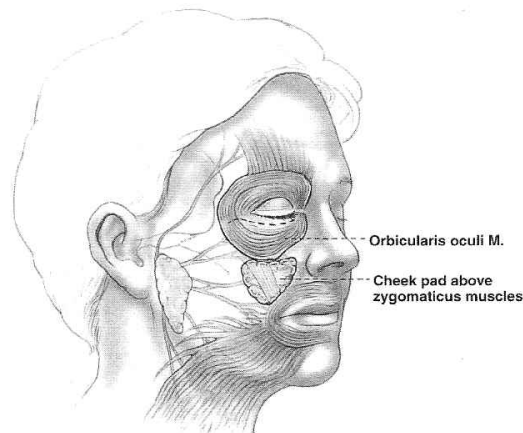
**Figure 1** The insertion of the temporal fascia varies depending on the location on the zygoma. (From Campiglio GL, Candiani P. *Aesthetic Plast Surg* 1997;21:72. Reprinted with permission.)

cia. The deep and ITF layers coalesce on the zygoma. The two components of the temporal aponeurosis (DTF and ITF) fuse above the zygoma, whereas in the central zygoma the fat pad inserts directly onto the zygoma, with no fusion of the layers. The frontal branch of the facial nerve becomes more superficial as it heads posteriorly along the zygoma.<sup>1</sup> Masseteric and zygomatic ligaments are noteworthy in that they may prevent upward mobilization of the flap in subperiosteal midfacial procedures.

**MIDFACIAL AGING AND LOWER EYELID SHAPE**

There are three infraorbital bulges resulting from laxity of the orbital septum. Periorbital fat atrophies globally around the eye. This results in a sunken appearance to

the eyes. The cheekpad and malar fat pad descend, with two consequences: first, the inferior orbital rim becomes apparent as it is “uncovered” by the descending cheekpad. Second, the cheekpad falls onto the nasolabial fold, deepening the nasolabial fold and thickening the tissue collecting above the fold. A prominent nasojugal groove and infraorbital hollow therefore develop as the cheekpad complex descends (Fig. 2). Orbicularis droop with relaxation of the orbicularis oculi muscle can contribute to festoon formation and descent of the cheekpad complex. Subcutaneous fat atrophy causes facial volume. As the cheekpad complex droops and subcutaneous fat atrophy occurs, the globe appears more forward set.<sup>2</sup>



**Figure 2** Ptosis of the orbicularis muscle, the cheekpad complex, and the malar fat pad deepen the nasolabial fold. Descent of the malar fat pad leaves the infraorbital rim exposed. (From Moelleken B. *Rejuvenation of the upper and midface*. In: Mathes et al., ed. *Plastic Surgery*. Philadelphia: WB Saunders; in press. Reprinted with permission.)

**POSTBLEPHAROPLASTY SEQUELAE**

It is necessary to treat postblepharoplasty syndromes when they are present and avoid them assiduously by intelligent surgical design. Midfacial procedures have been modified to treat midfacial retraction caused by aggressive blepharoplasty. Classically, an accurate diagnosis is made between the three lamellae and their contribution to the lower eyelid problem. The degree of horizontal or vertical shortening or laxity is determined to see how the reconstruction is to proceed. The most frequent postblepharoplasty problem is retraction of the anterior (skin and orbicularis muscle) and middle lamella (orbital septum). Surgeons with an interest in the midface now recognize that correction of the lower eyelid deformity most often involves midface elevation to make tissues available for reconstruction of the defect. Midfacial procedures performed in a subperiosteal plane may be associated with a higher incidence of ectropion than with a suborbicularis dissection for midfacial elevation.

There is an increasing incidence of lower eyelid problems such as ectropion, lateral canthal dystopia, and excessive scleral show resulting from the broader use of midfacial procedures.<sup>3</sup>

### LATERAL CANTHUS

The effect of brow-midface techniques on the lateral canthus can be predicted. Endoscopic midfacial elevation techniques performed through an incision above the hairline may raise the lateral canthus. This canthal elevation can at times be desirable, that is, when a post-blepharoplasty round eye deformity or a depressed lateral canthus is present. These techniques may also raise and distort the hairline. Tension that raises the midface must traverse a midpoint at the lateral canthal region and exert an upward vector on this area. If the lateral canthus is in the correct position, a combined brow-midface technique may have an undesirable effect on the lateral brow, creating the artifact of an overly high lateral canthus.

### MIDFACIAL TECHNIQUES

#### Arcus Marginalis Release

The arcus marginalis technique allows for distribution of infraorbital fat down into the infraorbital hollow, reducing infraorbital hollowness. This camouflage technique is useful not only as a primary technique but also as an adjunct for midfacial advancement techniques. In many patients with thin skin, the arcus marginalis technique alone does not suffice, and other techniques are required to rejuvenate the lower lid-cheek junction more completely. In the author's experience, there is a high incidence of persistent postoperative infraorbital bulge when the arcus marginalis release procedure is performed. The author has found it preferable to tighten the orbital septum and retain the fat in combination with a superficial cheeklift with upward midfacial tissue advancement.

#### Malar Fat Pad Elevation

Owsley advocated elevating in a superolateral vector the malar fat pad during a facelift.<sup>4,5</sup> In the author's experience, lifting the malar fat pad alone while performing a facelift does not tailor the orbicularis muscle or support the lateral canthus, necessary components of midfacial rejuvenation.

#### Redraping the Orbicularis Arc

To treat lower lid ectropion or to produce midfacial smoothing, redraping of the orbicularis arc with a lateral canthoplasty can be performed. The procedure involves drill hole fixation through the superolateral orbital bony rim to anchor the lateral canthus. This can be combined with spacer implants for middle lamellar deficiencies.<sup>6</sup> Other orbicularis redraping operations have

been proposed by Fogli,<sup>7</sup> Hinderer et al.,<sup>8</sup> and Trepsat.<sup>9</sup> The author has not found that a formal lateral canthotomy is not routinely necessary and may result in a break in the smooth lower eyelid shape.

### SUBPERIOSTEAL FACELIFT TECHNIQUES

The subperiosteal approach to a facelift may have special merit in younger patients or patients with preferential upper face and midface ptosis with minimal neck ptosis. With the exception of the transition from the temple to the zygomatic periosteum, the dissection is straightforward. There may be advantages to endoscopic techniques in smokers. The blood supply is probably preserved better than with an extended subcutaneous dissection can. For the same reason, there may be a greater margin of safety in combining full-face laser resurfacing with endoscopic temple and facelifts than with conventional facelifts.<sup>10</sup>

The Achilles' heel of the subperiosteal facelift has always been injury to the frontal branch of the facial nerve, significant postoperative swelling, and inadequate rejuvenation of the neck.

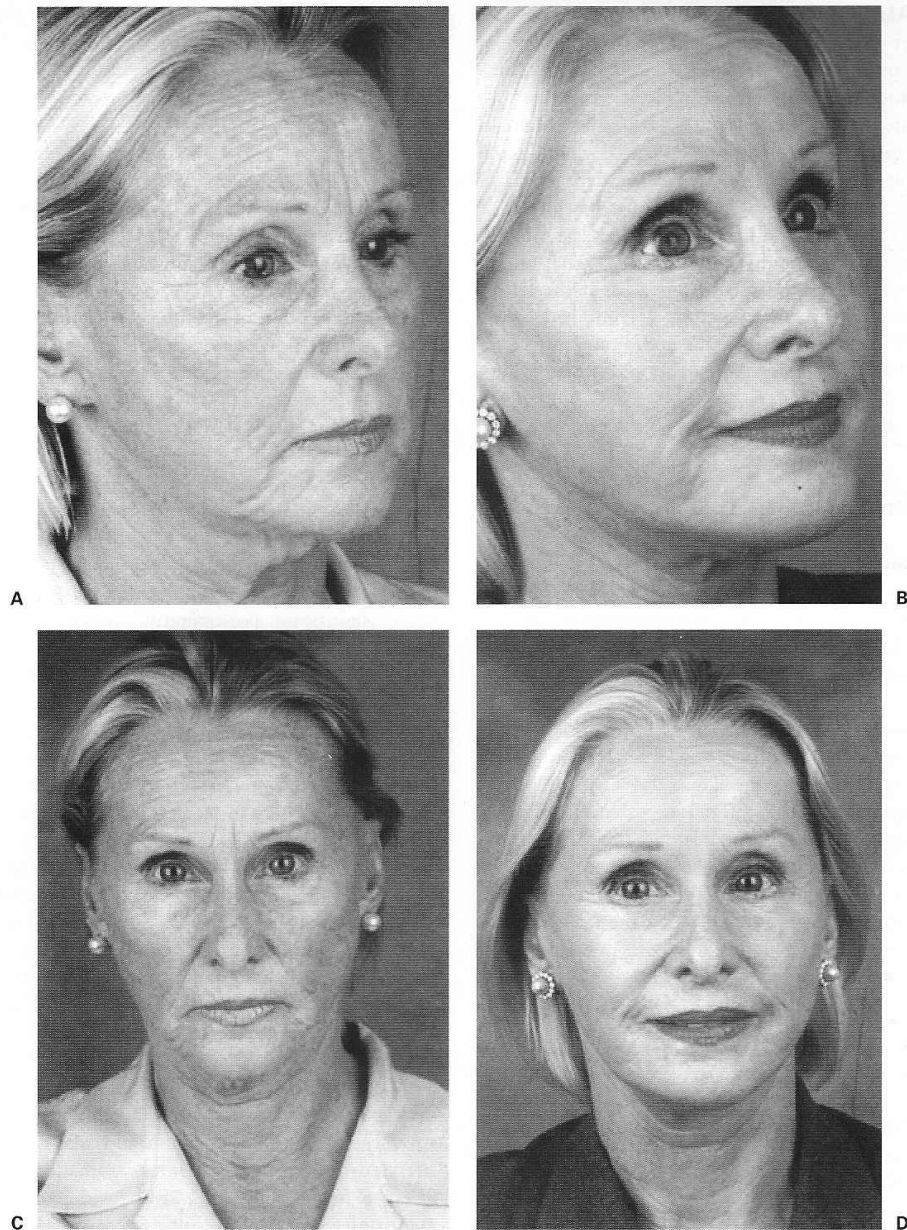Subperiosteal procedures for the upper and midface can be made through a temporal incision, either through endoscopic stab incisions or longer nonendoscopic temporal incisions. A second incision is then made through the gingivobuccal sulcus or a subciliary incision. A posterior approach to the zygoma at the level of the tragus may reduce the risk of frontal branch injury when mobilizing soft tissues off the zygoma. Cheekpad elevation in a superior-lateral vector can generally be achieved.<sup>11</sup>

Advantages of a purely subperiosteal upper and midfacelift with combined temporal and buccal sulcus incisions include ease of implementation, no necessity of infraorbital incision, and minimal risk of ectropion. The purely endoscopic upper and midfacelift technique is especially useful if modest elevation of the midface with no treatment of the orbicularis oculi muscle or neck is necessary. Care must be taken when performing any surgery that elevates midfacial tissue in a superior-lateral direction that the interzygomatic (intermalar) distance not become excessively wide, or a "praying mantis" deformity may result.

### MIDFACELIFTS FOR AVOIDANCE OF LATERAL SWEEP SYNDROME

The lateral sweep appearance of the face is avoided by lifting the midface as well as the side and bottom of the face and neck. (Fig. 3A-D).

A harmoniously rejuvenated face should include as many important youthful features with as few telltale signs and distortion of normal anatomy (Fig. 4A, B).



**Figure 3** (A, C) Preoperative view of a patient with previous facelift with no midface rejuvenation. (B, D) Postoperative views after elevation of the midfacial tissues with reduction of the "lateral sweep" phenomenon. (From Moelleken B. Rejuvenation of the upper and midface. In: Mathes et al., ed. *Plastic Surgery*. Philadelphia: WB Saunders; in press. Reprinted with permission.)

#### **MIDFACE ELEVATION IN POSTBLEPHAROPLASTY SYNDROME**

Midfacial elevation in combination with lateral canthal reconstruction is useful for patients with postblepharoplasty lower eyelid retraction, lateral canthal dystopia,

increased scleral show, round eye deformity, and often frank ectropion. Correction requires elevation of the midfacial tissues to efface the nasojugal groove and infraorbital hollowness plus grafting into the hollow region (Fig. 5A, B).<sup>12</sup>



**Figure 4** (A) Preoperative patient with previous facelift with midfacial sagging despite upper and lateral facial tightness. (B) Postoperative view of patient after a midfacial elevation (superficial cheeklift) along with a revisional facelift.

#### LATERAL CANTHAL TIGHTENING PROCEDURES

One effective technique for mild postblepharoplasty syndrome is lateral canthal elevation with mild undermining of the orbicularis muscle, leaving a cuff of orbicularis muscle. As described, this technique uses an optional canthotomy and drill fixation of the suspension suture. More aggressive techniques may necessitate wider midfacial elevation. Another approach is to combine midfacial elevation with lateral canthopexy. This combination can be used for microadjustment of the lateral canthus with midface elevation and rejuvenation (Fig. 6A, B).

#### MIDFACE-SUBORBICULARIS TECHNIQUE

Elevation of the midface and lateral face can be accomplished in a subcutaneous plane, a suborbicularis plane, or a subperiosteal plane. Elevation at the subcutaneous plane may neglect many of the deeper signs of aging, such as ptotic orbicularis muscle, infraorbital fat against the orbital septum, and ptotic malar fat pad. In a suborbicularis plane, it is possible to perform simultaneous lower blepharoplasty with treatment of fat herniation and orbicularis descent. An inherent advantage of a suborbicularis technique is the ability to correct a ptotic orbicularis muscle and an ability to move superficial soft tissues otherwise tethered by an unyielding periosteum. Risk to the frontal branch of the facial nerve is remote.

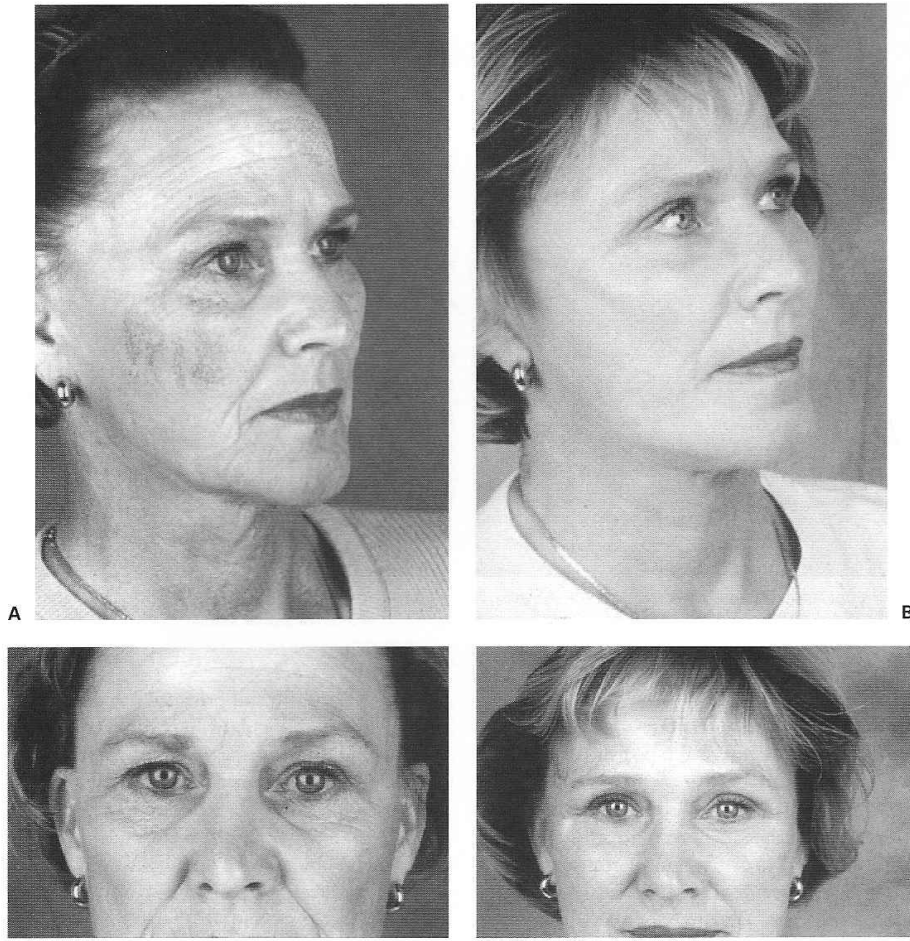If a 4- to 5-mm cuff of pretarsal orbicularis oculi muscle is maintained, orbicularis hypotonicity is very rare.

The zygorbicular plane of midfacial elevation is basically a suborbicularis approach to the midface. It also uses a second plane, underneath the medial portions of the zygomaticus major and minor. This technique is combined with a composite facelift, in which a composite facelift flap is created and rotated upward. However, a component of the composite lift may be an extreme elevation of the sideburn. In development of the composite flap as originally described, the pretarsal orbicularis oculi muscle is taken from its lower eyelid attachments with no cuff remaining on the lower eyelid.<sup>13</sup> The author has found that, when no cuff of pretarsal orbicularis muscle is left behind to support the lower eyelid, there is elevated potential for dystonia of the lower lid, ectropion, or lid retraction. Dissection at the suborbicularis level has inherently less swelling than when the subperiosteal space is entered.

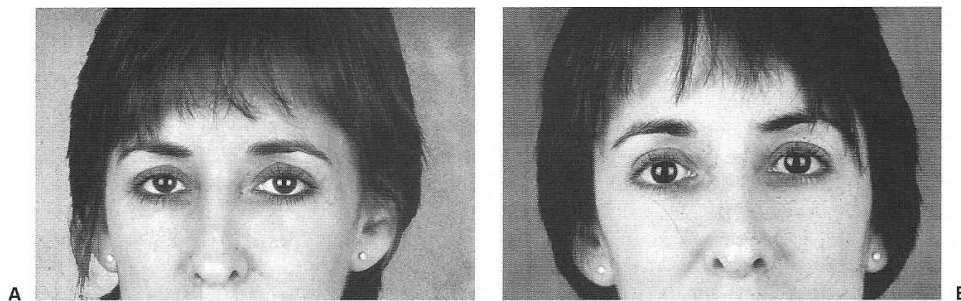
Many hybrid techniques are emerging that combine aspects of isolated techniques. In one such technique, a subperiosteal dissection is combined with a lateral temporal incision. Malar fat pad is elevated superolaterally and fixated to the DTF.

#### SUPERFICIAL CHEEKLIFT TECHNIQUE

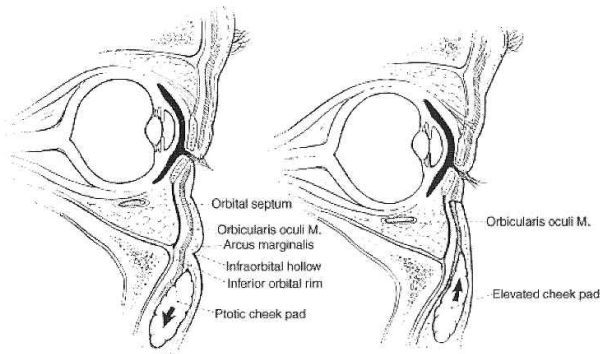
With the superficial cheeklift by Moelleken,<sup>14</sup> rejuvenation of the midface and lateral periorbital region can effectively be achieved by a midfacial and lateral peri-



**Figure 5** (A, C) Preoperative patient with postblepharoplasty hollowness. (B, D) Postoperative view after midfacial rejuvenation and arcus marginalis release with transposition of fat into infraorbital hollow. In patients such as this, dermal-fat-fascial grafts are now inserted into the infraorbital and nasojugal hollows. (From Moelleken B. Rejuvenation of the upper and midface. In: Mathes et al., ed. *Plastic Surgery*. Philadelphia: WB Saunders; in press. Reprinted with permission.)



**Figure 6** (A) Preoperative view of a patient with downward cant of the lateral canthus. (B) Postoperative view after selective elevation of the lateral canthus plus midfacial elevation. (From Moelleken B. Rejuvenation of the upper and midface. In: Mathes et al., ed. *Plastic Surgery*. Philadelphia: WB Saunders; in press. Reprinted with permission.)



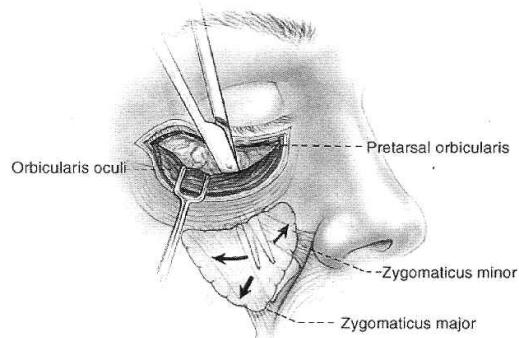
**Figure 7** Lateral view of the upper cheek anatomy. Note role of orbicularis oculi muscle (distal fibers) with malar fat pad. The SOOF layer, located deep to the orbicularis oculi muscle, is simply a gliding layer for the orbicularis muscle to function properly, in the opinion of the author. The SOOF is by itself not a structural layer capable of elevating and fixating the midfacial tissues. (From Moelleken B. *Plast Reconstr Surg* 1999; 104(6):1863–1874.)

orbital lift through a subciliary incision. The dissection is carried down through the orbicularis muscle, preserving a 4- to 5-mm cuff of pretarsal orbicularis muscle (Figs. 7–10). A suborbicularis dissection is then undertaken to free the malar fat pad and midface from their midfacial attachments. The entire midfacial complex is advanced superiorly and the cuff of cheek orbicularis is anchored to the ITF, located just lateral to the lateral orbital rim. Predictable rejuvenation of the midfacial and lateral periorbital region is possible. The extended healing time of the subperiosteal approach is avoided. The morbidity of a lateral canthotomy is also avoided. Microadjustment of the orbicularis oculi muscle is possible prior to closure of the subciliary incision. The published series of this procedure has a zero incidence of ectropion; the superficial cheeklift does require familiarity with the midface and lower eyelid and may be technically more difficult than midfacial techniques not performed through a subciliary incision.

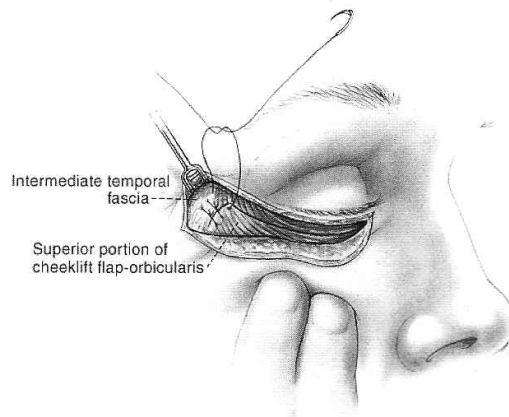
Complications have been minor and include palpable fixation sutures, subtle facet formation at the lateral inferior periorbital region, postoperative lateral periorbital incisional swelling, and visible scars requiring minor scar revisions. Using very short lateral periorbital incisions, carefully adjusting tension on the cheeklift flap, and taping of the lateral periorbital area for a period of 3 days postoperatively can minimize these complications. The author has had no ectropion problems in over 300 patients. In keeping with the trend for more comprehensive rejuvenation and fat preservation or restoration, dermis-fat or SMAS grafts can be placed in regions of excessive hollowness at the same time that the midfacial elevation is performed (Fig. 11).

This operation provides predictable elevation of midfacial tissues with effacement of the infraorbital hollow region in a technically straightforward plane of dissection (Figs. 12A, B, 13A–D).

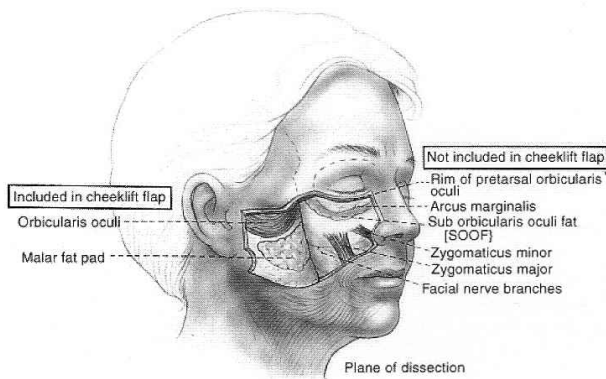
In men, the cheeklift increases the ability of the surgeon to remove skin conservatively while rejuvenat-



**Figure 8** Superficial cheeklift dissection with suborbicularis dissecting, preserving a pretarsal orbicularis cuff and avoiding lateral suborbicularis dissection. These two cautionary steps will avoid temporary or permanent denervation of the orbicularis with postoperative ectropion. (From Moelleken B. *Plast Reconstr Surg* 1999;104(6):1863–1874.)



**Figure 9** Securing of the elevated midfacial cheekpad complex to the ITF via the orbicularis muscle and its attachments to the malar fat pad. (From Moelleken B. *Plast Reconstr Surg* 1999;104(6):1863–1874.)



**Figure 10** The level of dissection of the superficial cheeklift is suborbicularis, leaving the zygomaticus muscles behind. (From Moelleken B. *Plast Reconstr Surg* 1999;104(6):1863–1874.)

ing the lower eyelid, a powerful tool in the correction of festoons or significant infraorbital aging, with the usual risk of lateral lower eyelid retraction (Fig. 14A–D).

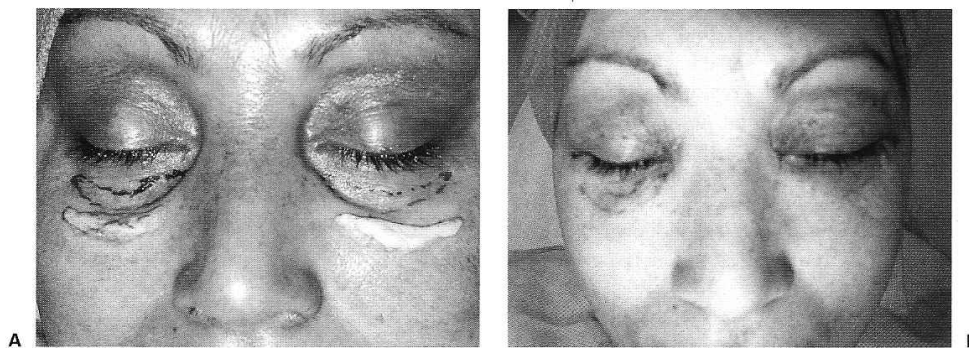**LIMITATION IN MIDFACIAL TISSUE ELEVATION**

There was a disturbing trend to maximize the amount of midfacial elevation during the performance of midfacial or upper facial–midfacial tissues. The amount of available tissue for elevation is very limited. Only approximately 1 cm<sup>2</sup> of tissue is generally available for resection and elevation. In patients with previous blepharoplasty, there is typically no tissue that can be resected. Rather, all elevated midfacial tissues are required to allow for correction of anterior and middle lamellar deficiencies. The author never attempts aggressive midfacial lifts.

**THE MIDFACIAL TEST**

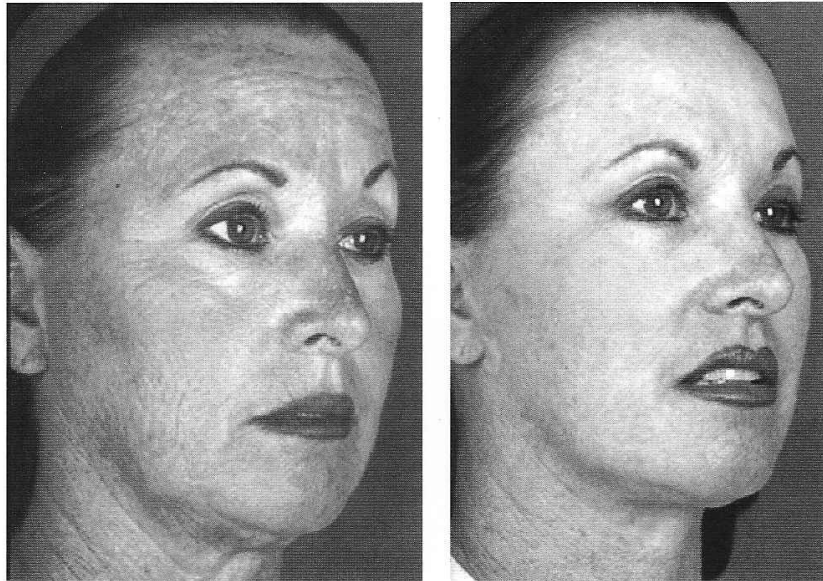Excessive elevation of midfacial tissues can result in ectropion, round eye deformity, and orbital exposure with keratopathy. In patients who have had aggressive midfacial elevation procedures, early signs of tightness in the midface are a downward lower eyelid pull when the patient opens his or her mouth and forces the upper lip over the front teeth. This serves as a very useful test. When the mouth is opened widely and the patient then forces the upper lip over the front teeth, retraction of the lower eyelid indicates that no additional midfacial tissue can be mobilized.

This deficit in midfacial tissue can result from middle lamellar scarring after aggressive blepharoplasty, from prior midfacial procedures, repair of facial fractures in a subperiosteal plane, and subperiosteal facelift techniques with scarring in the subperiosteal plane.



**Figure 11** (A) Intraoperative photograph showing SMAS grafts prior to placement in a region of infraorbital hollowness. (B) Intraoperative photograph shows both infraorbital regions after placement of the SMAS grafts. Midfacial elevation of left side completed, prior to elevation of right side. Direct placement of living autologous grafts will have higher reliability than aspirated and transplanted fat grafts. (From Moelleken B. *Rejuvenation of the upper and midface*. In: Mathes et al., ed. *Plastic Surgery*. Philadelphia: WB Saunders; in press. Reprinted with permission.)





**Figure 12** (A) Preoperative view of a woman with infraorbital hollowness and cheekpad complex ptosis. (B) Postoperative view after a superficial cheeklift in combination with a face and necklift, resulting in rejuvenation of the upper, mid-, and lower face.

### **SUBPERIOSTEAL SUBCILINARY PROCEDURES**

Many subperiosteal subciliary techniques are described with canthotomy and a subperiosteal dissection. Complications can be significant and include prolonged swelling associated with the subperiosteal dissection and lateral canthal distortion associated with a canthotomy. This technique and all midfacial techniques require considerable experience with the midface and lower eyelid. More recently, advocates of this technique have abandoned the canthotomy.<sup>15</sup>

The subperiosteal cheeklift, despite its difficulty and potential complications, can produce excellent midface elevation when performed by surgeons with expertise in midfacial procedures. It is important to avoid a long lateral periorbital incision and, whenever possible, to avoid a canthotomy. Because the periosteum is an unyielding layer, upward rotation of the flap may necessitate scoring from below of the periosteum during flap elevation.

### **TRANSMALAR SUBPERIOSTEAL MIDFACELIFT**

The transmalar subperiosteal midfacelift is a subperiosteal technique that anchors the zygomaticus muscle origins to the DTF and is accomplished with a blind dissection through the skin on the zygoma with minimal skin and SMAS undermining.<sup>16</sup> A theoretical disadvantage of this technique may be the concentration of the entire vector of the lift in a single suture. Temple

and gingival sulcus incisions are the most common locations of these incisions for these types of procedures.<sup>17</sup>

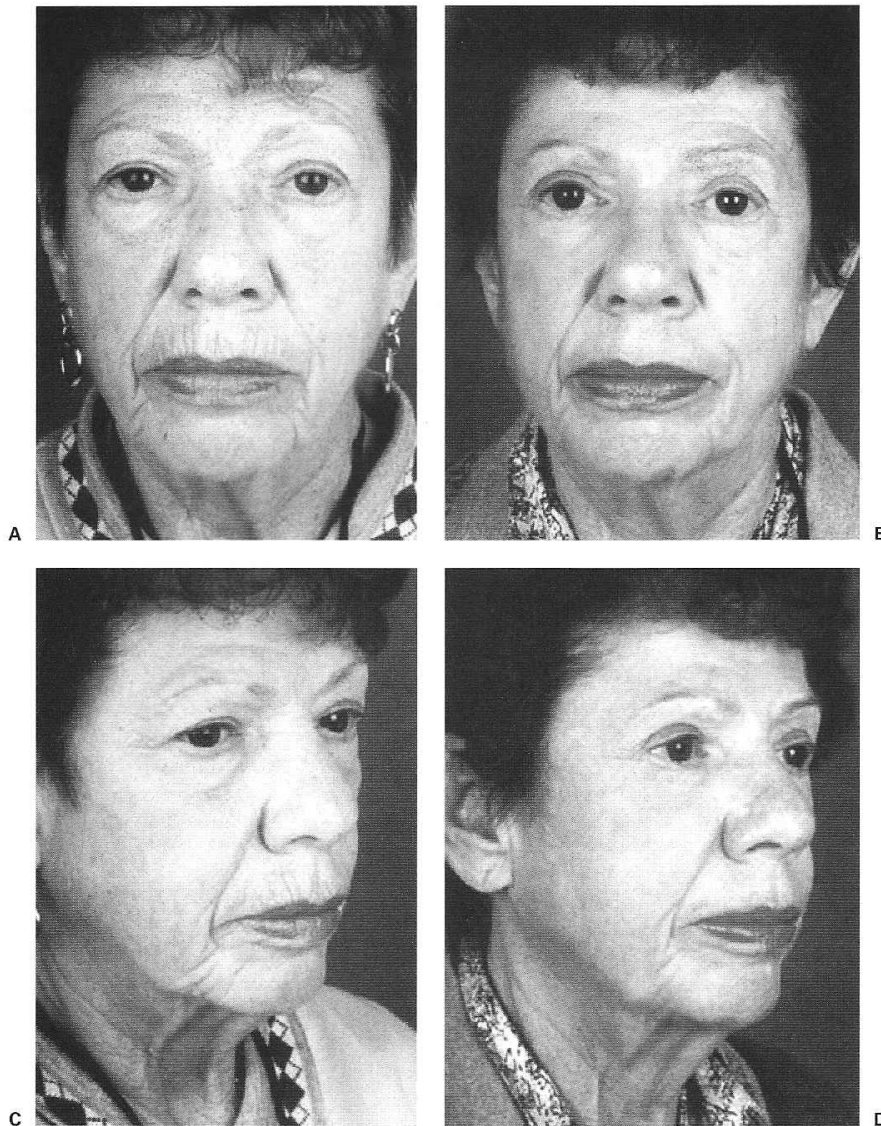### **ENDOSCOPIC MALAR/MIDFACE SUSPENSION**

Endoscopic, subperiosteal elevation is accomplished with anchoring of the midfacial tissues to the DTF with suspension sutures.<sup>18</sup> This may accomplish an elevation of midfacial tissues with suspension to the DTF. It does not involve a subciliary incision, so concomitant blepharoplasty requires a separate incision.

### **SINGLE-STITCH TECHNIQUES**

One hallmark of all standard techniques is that undermining is done in a relatively wide plane of the tissues to be elevated. Historically, there have been single-stitch techniques (i.e., the "Marionette" stitch) described that purport to elevate tissues based on a single suspension-type stitch with minimal or no undermining. These techniques have had recent interest, especially when combined with other procedures such as a facelift for additional tightening of the nasolabial fold.

Results from such techniques may be acceptable provided the midfacial stitch does not break or pull loose or exhibit lines of tension through the skin. However, the tension may be directed to a very small segment of tissue, and the pull may not elevate the adjacent



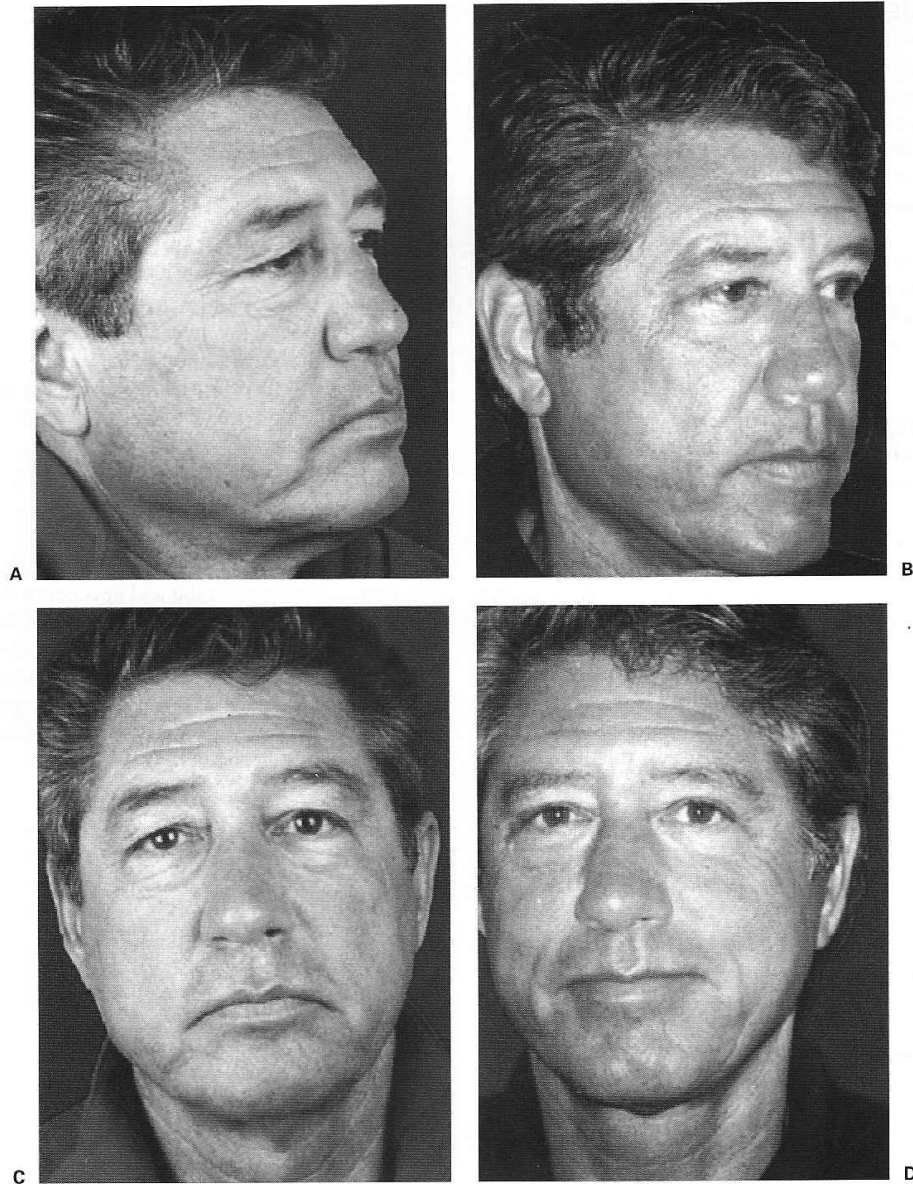
**Figure 13** (A, C) Preoperative patient troubled by periorbital aging and lip rhytids. (B, D) Postoperative views after full full-face CO<sub>2</sub> laser resurfacing, upper blepharoplasty, and midface elevation. Additional brow surgery would have resulted in excessive brow elevation. Patient did not desire neck rejuvenation. (From Moelleken B. Rejuvenation of the upper and midface. In: Mathes et al., ed. *Plastic Surgery*. Philadelphia: WB Saunders; in press. Reprinted with permission.)

tissues, resulting in visible lines of pull. If the stigmata of aging in a patient were isolated to a single locus, a single stitch might remedy this focal aging. Most patients, however, age over a broad plane and benefit from the broad undermining and elevation, a concept that all current tissue elevation techniques espouse. Most of the published techniques that espouse a single-stitch correction of the nasolabial fold show signs of concomitant facelift surgery on the photographs or are combined with other facial procedures such as facial laser, lower blepharoplasty fat injection, endoscopic facelift, and browlift.<sup>19</sup>

#### **SKELETAL AUGMENTATION TO ACHIEVE REJUVENATION (CHEEK OR COMPOSITE IMPLANTS)**

Augmentation of underlying bony structures in the supraorbital-temporal ridge area and malar-midface areas may counteract the effects of aging by filling in tissues lost to senile subcutaneous atrophy.<sup>20-22</sup>

The placement of cheek implants or submalar implants may successfully replace soft tissue loss due to subcutaneous tissue atrophy. Careful analysis of the facial zones and tissue deficits is essential. There is a ten-



**Figure 14** (A, C) Preoperative views of a man with aging face, eye, midface, and brows. (B, D) Postoperative views after facelift, cheeklift, extended upper blepharoplasty, and subtle lateral temporal browlift. An extended upper blepharoplasty combined with a lateral browlift results in minimal distortion of the temporal hairline yet offers adequate rejuvenation without feminization associated with excessive browlifting procedures in many male patients. (From Moelleken B. Rejuvenation of the upper and midface. In: Mathes et al., ed. *Plastic Surgery*. Philadelphia: WB Saunders; in press. Reprinted with permission.)

dency away from the older style “button implants” placed on top of the lateral zygoma, as these are often visible and unattractive. Increased intermalar distance, the “praying mantis effect,” should be avoided in placement of any midfacial implants.

When profound midfacial wasting is present (as with HIV patients who are taking multiple antiviral

medications), large pyriform aperture-midfacial implants can be fashioned based on a CT-scan, computer-generated moulage. The implants are then customized preoperatively and minor revisions performed in the operating room. Generally, an upper buccal sulcus incision is sufficient to place even very large custom implants in the midface and pyriform area.

### FAT INJECTION AND GRAFTING

Care must be taken not to inject fat into areas covered by excessively thin flaps, as the fat may then be visible as a subcutaneous irregularity. This fat presents a particular problem, as fat that does survive injection tends to be very fibrous and firm. One area that seems unsuited for routine fat injection is the infraorbital hollow region in patients with thin skin (Fig. 15A, B). Occasionally, injected fat can form calcific nodules, which require direct excision. In some circumstances, direct placement of SMAS or dermal-fat-fascial grafts into glabellar furrows, nasolabial folds, and infraorbital hollow regions may be preferable to fat injection.

### ENDOSCOPIC BROWLIFT-MIDFACELIFT

For two reasons, the difficult portion of the dissection is the transition from the ITF to the subperiosteal plane at the zygoma. First, the frontal branch of the facial nerve runs supraperiosteally from the tragus of the ear to a position 1.5 cm lateral to the lateral brow. This can be injured if the dissection is not strictly subperiosteal over the zygoma or if undue traction is placed in this relatively inflexible layer. Second, the transition from the DTF to the zygomatic subperiosteal plane involves transition over the temporal fat pad. If this is injured, a hollow appearance in the temple can result unilaterally or bilaterally. The author does not lift the midface at a

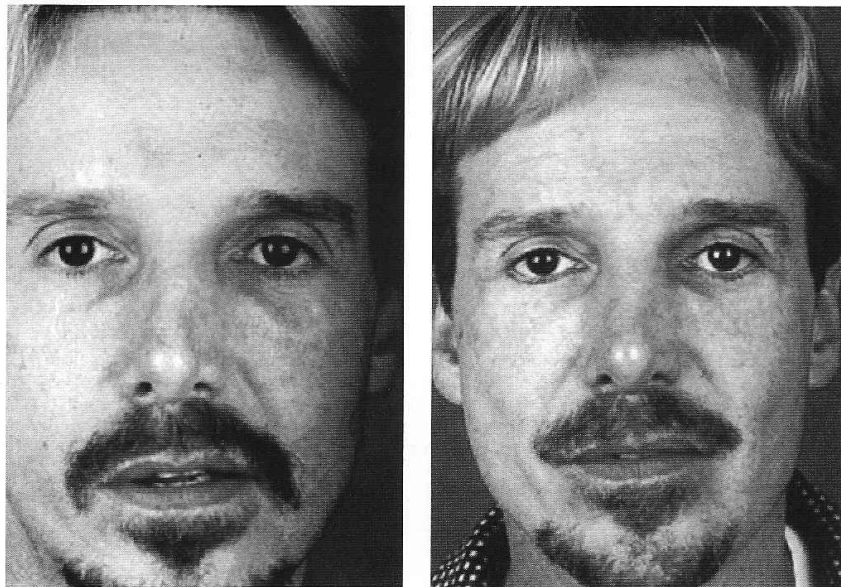
subperiosteal plane with techniques originating in the temple for three reasons: (1) hairline distortions caused by excessive elevation of the sideburn, (2) necessity of using a subperiosteal plane, with its attendant swelling, and (3) increase in the intermalar distance when the malar fat pad is positioned upward and to the side.

### BOTULINUM TOXIN AND MIDFACIAL REJUVENATION

Presently, it is inadvisable to use botulinum toxin on the crow's feet region of the orbicularis oculi muscle when a midfacelift is undertaken, usually for 1 month preoperatively and 3 to 6 months postoperatively, depending on the state of the lower eyelid tonicity, as temporary hypotonicity of the lower lid can result.

### CONCLUSION

The superficial cheeklift offers a low-risk approach to the midface and lower eyelid and operates in the desirable suborbicularis plane, avoiding a subperiosteal dissection. Midfacial tissue available for elevation is very limited. This article provides a useful technique for assessing available midfacial tissue. There are specific indications for midfacelifts for midfacial rejuvenation and correction of postblepharoplasty syndromes.



**Figure 15** (A) Preoperative view of a patient who had previously undergone subcutaneous fat injection, which survived as a lumpy subcutaneous growth. The patient had failed attempts at removal of the fat with liposuction and direct excision and suffered from dry eye syndrome and lateral canthal dystopia. (B) Postoperative view after removal of fat, canthal reconstruction, and superficial cheeklift. (From Moelleken B. Rejuvenation of the upper and midface. In: Mathes et al., ed. *Plastic Surgery*. Philadelphia: WB Saunders; in press. Reprinted with permission.)

## REFERENCES

1. Campiglio GL, Candiani P. Anatomical study on the temporal fascial layers and their relationships with the facial nerve. *Aesthetic Plast Surg* 1997;21:72
2. Yaremchuk MJ. Subperiosteal and full-thickness skin rhytidectomy. *Plast Reconstr Surg* 2001;107:1585
3. Mendelson BC, Muzaffar AR, Adams WP. Surgical anatomy of the midcheek and malar mounds. *Plast Reconstr Surg* 2002 Sep;110(3):885-911
4. Owsley JQ. Lifting the malar fat pad. *Plast Reconstr Surg* 1993;91:463
5. Owsley JQ, Zweifler M. Midface lift of the malar fat pad: technical advances. *Plast Reconstr Surg* 2002;110(2):674-685
6. McCord CD, Codner MA, Hester TR. Redraping the inferior orbicularis arc. *Plast Reconstr Surg* 1998;102:2471
7. Fogli AL. Orbicularis muscleplasty and facelift: a better orbital contour. *Plast Reconstr Surg* 1995;96:1560
8. Hinderer UT, Urriolagoita F, Vildosola R. The blepharopriorbitoplasty: anatomical basis. *Ann Plast Surg* 1987;18:437
9. Trepsat F. Facelift of the malar, jugal and nasolabial regions. *Ann Chir Plast Esthet* 1994;39:597
10. Ramirez OM, Pozner JN. Subperiosteal minimally invasive laser endoscopic rhytidectomy: the SMILE facelift. *Aesthet Plast Surg* 1996;20(6):463-470
11. Namazie AR, Keller GS. Current practices in endoscopic brow and temporal lifting. *Facial Plast Surg Clin North Am* 2001;9(3):439-451
12. Edelstein C, Balch K, Schorr N, Goldberg RA. The transeyelid subperiosteal midface-lift in the unhappy post-blepharoplasty patient. *Semin Ophthalmol* 1998;13(3):107-114
13. Hamra ST. The zygorbicular dissection in composite rhytidectomy: an ideal midface plane. *Plast Reconstr Surg* 1998;102(5):1646-1657
14. Moelleken B. The superficial subciliary cheeklift, a technique for rejuvenating the infraorbital region and nasojugal groove: a clinical series of 71 patients. *Plast Reconstr Surg* 1999;104(6):1863-1874
15. Gunter JP, Hackney FL. *Plast Reconstr Surg* 1999;103(7):2029-2035
16. Finger ER. A 5-year study of the transmalar subperiosteal midface lift with minimal skin and superficial musculoaponeurotic system dissection: a durable, natural appearing lift with less surgery and recovery time. *Plast Reconstr Surg* 2001;15:107(5):1273-1283
17. Hobar PC, Flood J. Subperiosteal rejuvenation of the midface and periorbital area: a simplified approach. *Plast Reconstr Surg* 1999;104(3):842-851
18. Anderson RD, Lo MW. Endoscopic malar/midface suspension procedure. *Plast Reconstr Surg* 1998;102(6):2196-2208
19. Sasaki GH, Cohen AT. Meloplication of the malar fat pads by percutaneous cable-suture technique for midface rejuvenation: outcome study (392 cases, 6 years' experience). *Plast Reconstr Surg* 2002;110(2):635-654
20. Whitaker LA, Bartlett SP. Skeletal alterations as a basis for facial rejuvenation. *Clin Plast Surg* 1991;18(1):197-203
21. Binder WJ. Submalar augmentation: a procedure to enhance rhytidectomy. *Ann Plast Surg* 1990;24(3):200-212
22. Binder WJ, Moelleken BRW, Tobias G. Aesthetic facial implants. In: *Facial Plastic and Reconstructive Surgery*. New York: Thieme Medical Publishers; 2002
23. Campiglio GL, Candiani P. Anatomical study on the temporal fascial layers and their relationships with the facial nerve. *Aesthetic Plast Surg* 1997;21:72
24. Moelleken B. Rejuvenation of the upper and midface. In: Mathes et al., ed. *Plastic Surgery*. Philadelphia: WB Saunders; in press
25. Moelleken B. The superficial subciliary cheeklift, a technique for rejuvenating the infraorbital region and nasojugal groove: a clinical series of 71 patients. *Plast Reconstr Surg* 1999;104(6):1863-1874