

Plastic Surgery

Second Edition

Editor

Stephen J. Mathes, MD

Professor of Surgery
Chief, Division of Plastic Surgery
University of California, San Francisco
School of Medicine
San Francisco, California

Editor, Hand Surgery Volumes

Vincent R. Hentz, MD


Professor of Surgery
Chief, Division of Plastic and Hand Surgery
Stanford University School of Medicine
Stanford, California

With illustrations by Kathy Hirsh and Scott Thorn Barrows, CMI, FAMI

Shireen L. Dunwoody, Editorial Coordinator

VOLUME *I*

GENERAL PRINCIPLES



Volume I General Principles
Volume II The Head and Neck, Part 1
Volume III The Head and Neck, Part 2
Volume IV Pediatric Plastic Surgery
Volume V Tumors of the Head, Neck, and Skin
Volume VI Trunk and Lower Extremity
Volume VII The Hand and Upper Limb, Part 1
Volume VIII The Hand and Upper Limb, Part 2

Rejuvenation of the Upper Face and Midface: Current Techniques

BRENT MOELLEKEN, MD, FACS

AGING UPPER THIRD OF THE FACE

TRENDS

CHOICE OF BROW REJUVENATION TECHNIQUES

RELEVANT ANATOMY

- Features of the Aging Brow
- Features of the Aging Periorbital Region
- Brow Position Aesthetics
- Lateral Canthus

TREATMENT OF THE HAIRLINE

- Correction of the High Anterior Hairline
- Correction of Temporal Hair Loss
- Direction of Incision in Hairline
- Ear Incisions

FOREHEAD AND BROW LIFTS

- Direct Minimally Invasive Brow Lift Rejuvenation Procedures
- Muscle Division Techniques
- Nerve Ablation Techniques
- Single-Stitch Techniques
- Coronal Brow Lift
- Upper Eyelid Blepharochalasis
- Male Brow Surgery
- Endoscopic Brow Lift

- Temporal Lift
- Brow Lowering Techniques
- Botulinum Toxin
- Laser Resurfacing

MIDFACIAL AGING

- Arcus Marginalis Release
- Malar Fat Pad Elevation
- Redraping the Orbicularis Arc
- Cervicofacial Hike Procedure
- Subperiosteal Face Lift Techniques
- Combined Subperiosteal Techniques
- Composite Face Lift Technique
- Midface Lifts for Avoidance of Lateral Sweep Syndrome
- Postblepharoplasty Sequelae in Facial Rejuvenation
- Crow's-Feet
- Midface Suborbicularis Technique
- Superficial Cheek Lift Technique
- Limitations in Midfacial Tissue Elevation
- Subperiosteal Subciliary Procedures
- Endoscopic Midface Techniques
- Asian Face Lifts
- Skeletal Augmentation to Achieve Rejuvenation (Cheek or Composite Implants)
- Fat Injection and Grafting

AGING UPPER THIRD OF THE FACE

As surgeons who rejuvenate the face, our goals are simple: reverse as many of the signs of aging and do as little harm as possible in the process. A plastic surgeon cannot return the full, undamaged nature of youthful skin (Table 47-1). One can only focally reverse the atrophy that occurs with age. The successful surgeon will have a variety of techniques to customize a surgical plan for a patient and keep the goals and limitations of facial rejuvenation in perspective.

Many features of aging, such as midfacial aging, orbicularis drooping, brow ptosis with thinning hairlines, and fat and periorbital fat atrophy, can now be addressed. Essential treatments include composite grafting for hollow regions, fat preservation in periorbital surgery, and lower eyelid and midfacial

rejuvenation. Through skin care and lighter interventions, such as peels and resurfacing with various lasers, it is possible to improve and restore the quality of skin and reduce fine rhytids and sun damage. In vulnerable patients, customized brow lifts avoid hairline disturbances while addressing many of the signs of aging. Botulinum toxin focally addresses rhytids that formerly required invasive surgeries or surgeries that imperfectly or at great price rejuvenated these areas.

Yet unsolved are problems of aging skin surfaces and fat atrophy, specifically facial and periorbital fat atrophy; atrophy of the temporal fat pad, buccal fat pad, and malar fat pad; and global fat atrophy in the subcutaneous tissue. New understanding of anatomy has caused a renaissance in rejuvenation of the upper face and midface. The understanding of the relationship between the midface and the remainder of the face is still evolving.

TABLE 47-1 ♦ AGING OF THE UPPER FACE: AESTHETIC WISH LIST FOR REJUVENATION

Downward descent of lateral brow (anterior hairline lifts, lateral subperiosteal lifts, temporal lifts, coronal brow lifts, Botox)
Downward descent of central brow (anterior hairline brow lifts, coronal lifts, muscle resection techniques, Botox)
Hollowness of temporal fat pad (fat grafting)
Subcutaneous fat loss due to senile fat atrophy (no solution; fat grafting)
Vasodilation and exposure of small forehead veins (sclerotherapy or V-beam laser therapy)
Sun damage lesions (laser resurfacing, chemical peels, PhotoFacial treatments, N-Light laser, skin care, sun avoidance)
Epidermal and dermal atrophy (Retin-A, microdermabrasion)
Weakening of the periorbital septa with fat herniation (blepharoplasty)
Periorbital fat atrophy with subcutaneous volume loss (volume-sparing blepharoplasty with midfacial elevation; orbital septal plication)
Globe hollowness and sinking due to periorbital fat atrophy (no treatment)
Superior orbital blepharochalasis (blepharoplasty, lateral brow lift, combination of blepharoplasty and lateral brow lift)
Inferior orbital blepharochalasis (blepharoplasty; midfacial rejuvenation procedures)
Nasojugal groove deepening (cheek lift procedures; autologous fat grafting, tear trough-type implants)
Midfacial complex ptosis (cheek lift techniques; arcus marginalis technique; facial volume augmentation)
Orbicularis oculi ptosis (suborbicularis cheek lift techniques; canthopexy)
Horizontal forehead rhytids (Botox, lateral brow lift techniques; coronal brow lifts)
Glabellar rhytids (Botox; muscle division-resection techniques; nerve ablation techniques; coronal lifts)
Perinasal rhytids (Botox, skin care, nasal augmentation)
Crow's-feet (suborbicularis cheek lift techniques; temporal or lateral brow lift techniques; Botox)
Thinning and loss of hair at anterior hairline, temporal hairline, sideburn (hair transplantation; if iatrogenic, hair-restoring flaps and modification of vectors in revisional face lift)
Lightening (graying) of anterior hairline, temporal hairline, sideburn (hair coloring)
Darkening of the corneal surface (no treatment)
Thinning and loss of eyelashes (no treatment)
Lateral canthal ligament ptosis (lateral canthopexy)
Ptosis or rupture of the levator mechanism of the upper eyelid (levator aponeurosis repair)
Nasolabial fold heaviness and folds (face lift, midface lift-cheek lift, autologous tissue transplantation to nasolabial folds, temporary fillers)
Buccal fat pad atrophy (no treatment)
Malar fat pad atrophy (autologous tissue transplantation)
Lip atrophy (autologous tissue transplantation)
Upper lip lengthening (lip lifts; laser resurfacing)
Platysmal ptosis and banding (platysmaplasty with face and neck lift; platysmaplasty alone; Botox focally)
Facial skin and fat descent (face lift, neck lift, soft tissue augmentation)

TRENDS

The recent history of facial rejuvenation can be viewed as a series of trends toward avoidance of undesirable conspicuous effects of the rejuvenation process. Specific areas in which attention has been stressed are hairline preservation, avoidance of overresection, and periorbital fat preservation. Elevation of the midface with the lateral and lower face, customized brow lifting procedures, and use of fat and composite grafts to replace tissues lost to fat atrophy have enhanced results and avoid excessive incisions. It is now entirely possible to rejuvenate the brow by selectively reducing muscle activity in specific areas without lifting anything. Hence, the coronal brow lift as a sole option in rejuvenating the brow is superseded by several smaller and more targeted operations.

CHOICE OF BROW REJUVENATION TECHNIQUES

The decision whether to perform a coronal lift, an endoscopic lift, a minimally invasive direct brow lift,

a selective muscle resection, or the injection of Botox is complex and cannot be predetermined by mathematical algorithms. Rather, a careful discussion with patients elicits the troubling aspects of their appearance and their expectations.¹

RELEVANT ANATOMY

The deep temporal fascia is the covering in the temple of the temporalis muscle. Above it, containing the superficial temporal vessels, is the superficial temporal fascia. The intermediate temporal fascia and deep temporal fascia surround the temporal fat pad; the superficial temporal fascia, which continues below the zygoma as the superficial musculoaponeurotic system (SMAS), is superficial to the intermediate temporal fascia. The intermediate temporal fascia and the deep temporal fascia then insert onto the zygomatic periosteum from above. The tissue above the zygomatic periosteum contains the frontal branch of the facial nerve, which originates at the tragus of the ear and courses 1 cm lateral to the lateral brow into the

forehead musculature. There is no natural plane between the intermediate temporal fascia and the deep temporal fascia into the zygomatic subperiosteal space. Because the dissection is subperiosteal, upper face and midface procedures superior to the zygomatic arch require a clear understanding of forehead anatomy, and careful dissection must be undertaken. The surgeon must dissect through the intermediate temporal fascia into the temporal fat pad space, then proceed into the zygomatic subperiosteal space.

The exact anatomy is complex and controversial in the temple area, probably because the layers are so thin and change over the zygoma. Dispute has been particularly contentious over what exactly happens between the temporal fat pad and the zygoma and whether this changes over the course of the zygoma from anterior to posterior.²⁻⁵ Aspects of anatomy that are well accepted include the following. The deep temporal fascia, which forms the floor for the temporal fat pad, is a discrete entity (Fig. 47-1). The intermediate temporal fascia forms the roof and is separate from (and deep to) the SMAS-superficial temporal fascia. The deep and intermediate temporal fascial layers coalesce on the zygoma. Most likely, the two leaflets of the temporal aponeurosis (deep temporal fascia and intermediate temporal fascia) fuse above

the zygoma, except in the central zygoma, where the fat pad inserts directly onto the zygoma, with no fusion of the layers. The frontal branch becomes more superficial as it heads posteriorly along the zygoma.⁶ Masseteric and zygomatic ligaments may hinder upward mobilization of midface layers (Fig. 47-2).

The midface has been defined as the region from the lower eyelid (or the zygomatic prominence) to the nasolabial fold and oral commissure. There has been a further subdivision of the midfacial region into the prezygomatic portion overlying the body of the zygoma and maxilla and the infrazygomatic portion covering the oral vestibule.⁷ Because the orbital septum, arcus marginalis, and inferior orbital rim are so integral to rejuvenation of the midface, they are probably best included with the midface.

The orbicularis retaining ligament above and the zygomatic-cutaneous ligament below define the prezygomatic space (Fig. 47-3). Below the zygomatic-cutaneous ligament courses the main motor branch to the orbicularis oculi muscle. In performance of any sub-orbicularis midface elevation, these ligaments are defeated to allow untethered upward rotation of the malar fat pad complex. Injury to the zygomaticofacial nerve and motor branches to the orbicularis oculi is avoided. During the downward dissection of a

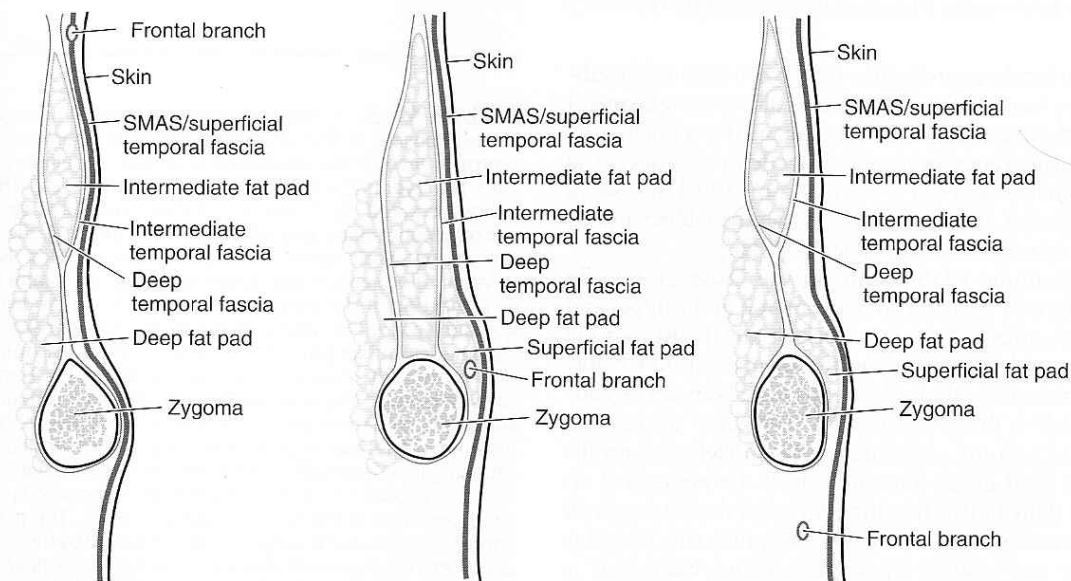


FIGURE 47-1. Anatomy at temple-zygoma junction. The zygomatic anatomy is particularly important as it relates to endoscopic brow lifts. Note that the insertion of the temporal fascia varies according to the location on the zygoma. The deep temporal fascia and intermediate temporal fascia coalesce into the periosteum of the zygoma at the anterior and posterior thirds of the zygoma only. In the central zygoma, the insertion of the intermediate temporal fascia and of the deep temporal fascia is directly onto the zygoma. In the endoscopic brow lift, the plane of dissection is superficial to the intermediate temporal fascia until just before its insertion onto the zygoma. At this point, the dissection requires division of the intermediate temporal fascia to gain access into the space occupied by the temporal fat pad and, from there, the subperiosteal plane on the zygoma. (From Campiglio GL, Candiani P: Anatomical study on the temporal fascial layers and their relationships with the facial nerve. *Aesthetic Plast Surg* 1997;21:72.)

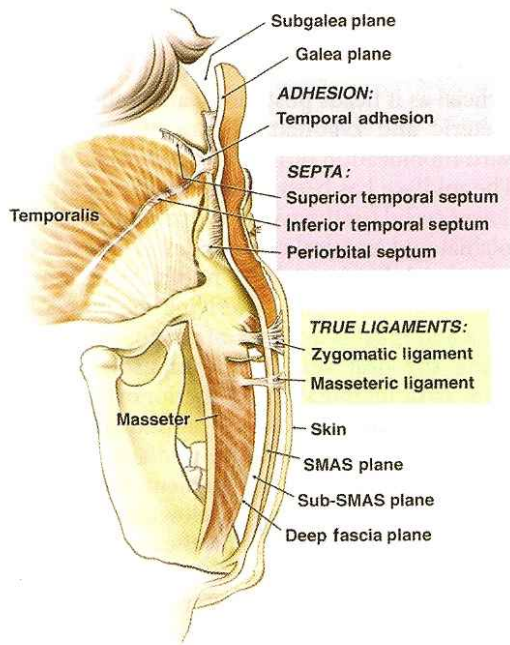


FIGURE 47-2. The zygomatic and masseteric ligaments limit upward pull of the temple-midfacial flap. The temporal muscle is bound by the inferior and superior temporal septa, which coalesce anteriorly at the temporal adhesion. (From Moss CJ, Mendelson BC, Taylor GI: Surgical anatomy of the ligamentous attachments in the temple and periorbital regions. *Plast Reconstr Surg* 2000;105:1477.)

suborbicularis procedure performed through a subcutaneous incision, the orbicularis oculi retaining ligament is first defeated (it is often accompanied by a small vein). Next, the zygomatic ligaments are defeated. The central zygomatic ligament is often accompanied by a small vein as well. Defeating these ligaments enables tension-free upward rotation of the malar fat pad.

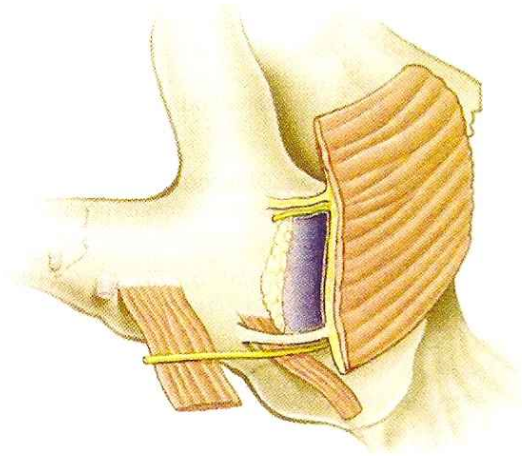
Anatomic relationships in the lower eyelid and midface are germane to rejuvenation of the upper and middle thirds of the face. Periorbital fat cushions the globe and is retained by the orbital septum below and the globe above. With age (and sometimes congenitally), the periorbital fat “herniates” against the orbital septum, weakening it. Most likely, this results from fluid fluxes into and out of the periorbital fat on a daily basis, stretching the orbital septum. As all subcutaneous fat in the face atrophies with age, this bulge can assume more prominence because it is accompanied by loss of fat elsewhere in the face. It is believed that the orbicularis oculi muscle becomes ptotic with age and droops. The pretarsal orbicularis muscle gives tonicity to the lower eyelid. Squinting with the eyes tightens this muscle. It is best with any midfacial procedure to leave a cuff of pretarsal orbicularis behind so that the lower eyelid does not lose tone and cause a temporary or permanent ectropion (Fig. 47-4). Preoperative assessment of the lower

canthal ligament is important because its tonicity will determine which procedure is performed to rejuvenate the face. A horizontally or vertically lax lower eyelid may warrant a canthopexy or canthoplasty, and the surgeon should exercise caution in performing midfacial or combined mid-upper facial rejuvenation procedures to avoid causing an ectropion in such a high-risk patient.

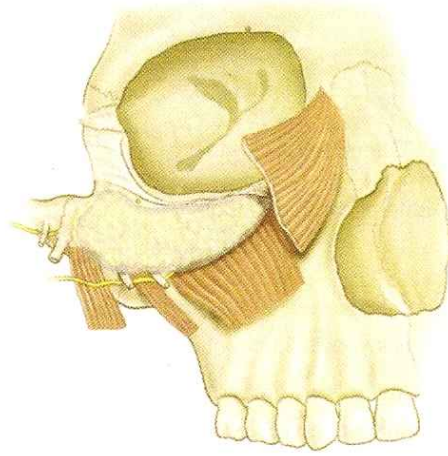
The orbital septum inserts into the inferior orbital rim. Undue tightening or scarring within the orbital septum can lead to middle lamellar scarring, a proven cause of severe ectropion. Caution must be used in performing orbital septal resecting or tightening procedures. It is important not to cause contraction in the orbital septum. This represents the middle lamella. If middle lamellar shortening develops, ectropion and vertical lid shortening result; this ectropion is refractory to conventional canthopexy.

Orbicularis oculi muscle innervation is primarily from inferiorly and laterally through the facial nerve. Therefore, one must be cautious in performing lower eyelid procedures on patients who have had recent Botox injections in the crow’s-feet region. It is important to avoid injury to the main motor branch of the orbicularis oculi muscle, lest prolonged postoperative hypotonicity of the lower eyelid result. The motor branch is located inferior to the zygomatic ligaments.

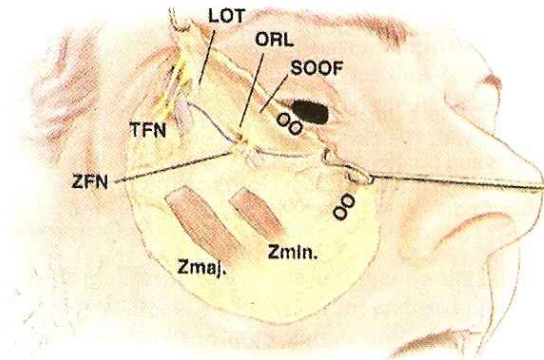
FIGURE 47-3. *A*, Note the zygomaticofacial nerve and its relationship to the orbicularis retaining ligament, the motor branch to the orbicularis oculi and its relationship with the zygomatic-cutaneous ligament, and the three spaces created by these structures—preseptal space, prezygomatic space, and infrazygomatic space. *B*, View of the prezygomatic space, with lip elevator muscles. Note location of orbicularis and zygomatic retaining ligaments. *C*, Dissection of the floor and upper border of the prezygomatic space. The origins of zygomaticus major (Zmaj.), zygomaticus minor (Zmin.), and levator labii superioris are also present. It is possible to traverse below the temporal branches to the orbicularis oculi (TFN) by remaining subperiosteal if this region is approached from above. Note locations of lateral orbital thickening (LOT), orbicularis retaining ligament (ORL), orbicularis oculi (OO), and sub-orbicularis oculi fat (SOOF). *D*, The prezygomatic space. Note positions of the suborbicularis oculi fat. The prezygomatic membrane (Pre Zyg. Memb.) is bound by the orbicularis retaining ligament above and the zygomatic ligament (ZL) below. The position of the motor nerve to the orbicularis is below, at the level of the remaining zygomatic ligaments, outside the prezygomatic space. *E*, Innervation of the orbicularis oculi muscle. Three common surgical approaches to the prezygomatic space are indicated. Numbers indicate facial nerve branches innervating the orbicularis oculi muscle. *F*, Cutaneous positions of the prezygomatic space, the orbicularis oculi ligament, and the zygomatic ligament. (From Mendelson BC, Muzaffar AR, Adams WP Jr: Surgical anatomy of the midcheek and malar mounds. *Plast Reconstr Surg* 2002;110:885-896.)



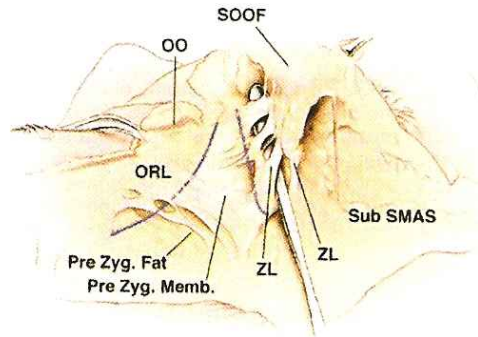
A



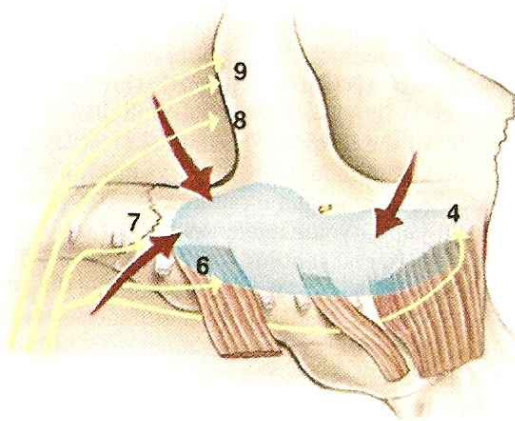
B



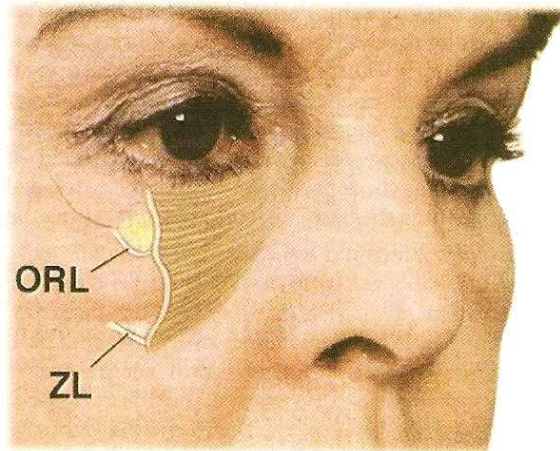C



D



E



F

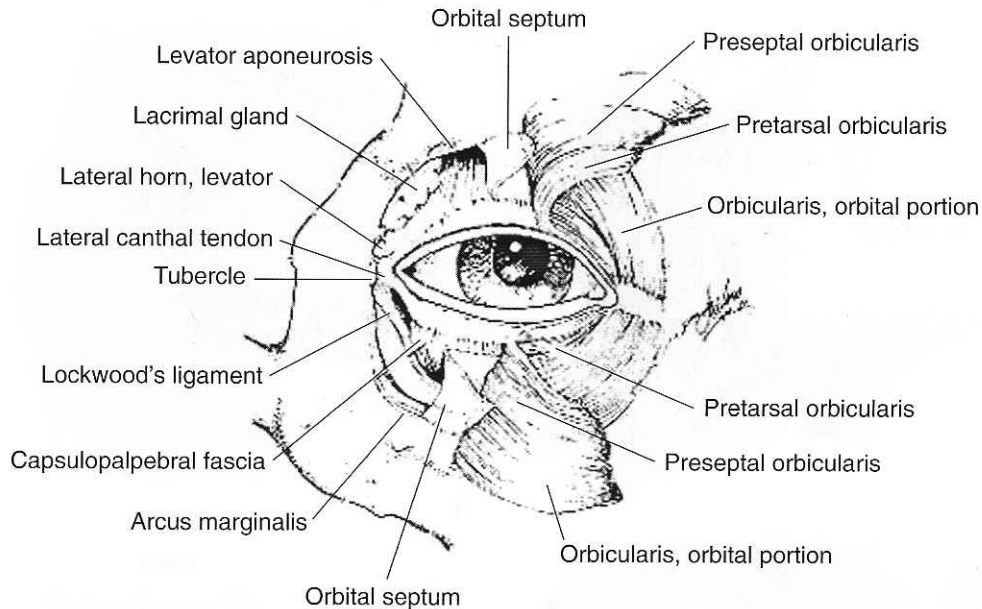


FIGURE 47-4. Anatomy of the orbicularis oculi muscle. Note the many functions of this muscle: the pretarsal orbicularis above the upper eyelid assists with eye closure, and the orbital portion forms brow furrows in combination with the corrugators and procerus muscles. The pretarsal orbicularis is also largely responsible for lower eyelid tonicity. The orbital septum inserts on the inferior orbital rim at the arcus marginalis. (From McCord CD, Codner MA, Hester TR: Redraping the inferior orbicularis arc. *Plast Reconstr Surg* 1998;102:2471.)

Features of the Aging Brow

The lower eyelids develop laxity of the inferior canthal ligament. Three infraorbital bulges result from laxity of the orbital septum. Periorbital fat atrophies globally around the eye; this results in a sunken appearance to the eyes. There is descent of the cheek pad and malar fat pad. This cheek pad descent has two direct effects: first, the inferior orbital rim becomes apparent as it is “uncovered” by the descending cheek pad; and second, the cheek pad descends onto the nasolabial fold, deepening the nasolabial fold and thickening the tissue collecting above the fold.

The mechanics of brow aging have been studied anatomically. The lateral brow ages earlier than the central brow. The descent of the lateral brow is due to the complex interaction of gravity and the corrugator supercilii, the frontalis, the galeal fat pad, the preseptal fat pad, and the subgaleal fat pad glide space.⁸

Features of the Aging Periorbital Region

The projection of the cheek pad anteriorly can be juxtaposed to the projection of the globe. With youthful faces, the cheek projects approximately 1.5 mm anterior to the globe. In older faces, a negative vector develops, with the cheek repositioned approximately

2.5 mm behind the position of the globe. This relationship change of cheek to orbit reflects the ptosis of the cheek pad complex and subcutaneous fat atrophy.⁹

In white women, the median height of the central eyebrow from the midpupillary level is 23 mm. The distance between the infraorbital sulcus and the lower eyelid margin is 12 mm.⁹ The medial brow ideally ends on a vertical line from the medial canthus and the lateral border of the nasal ala. The lateral brow should terminate in an oblique line drawn from the ala of the nose through the lateral canthus.

Eye shape in youth resembles more of an apex lateral slant; the lateral canthus is approximately 4 degrees higher laterally than the medial canthus (Fig. 47-5). The lateral to medial canthal distance is typically 31 mm. With age, the lateral canthal ligaments weaken and droop, causing increased scleral show as the lower eyelid droops inferiorly.

Brow Position Aesthetics

Excessive elevation of the medial brow causes a startled, surprised expression and is to be avoided. There is an alarming trend in the literature to measure success by the degree of elevation of different brow points. Excessive elevation of the lateral brow also results in an overly animated, artificial-appearing facial

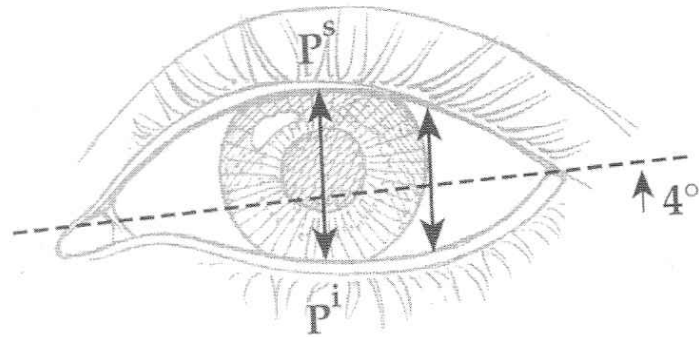


FIGURE 47-5. Aesthetic goals in lateral canthal rejuvenation. There is a 4-degree upward slant medial to lateral in young white women. (From Yaremchuk MJ: Subperiosteal and full-thickness skin rhytidectomy. *Plast Reconstr Surg* 2001;107:1585.)

expression. A lateral brow with a horizontal aspect to the medial brow in men or a slightly elevated aspect in women is aesthetically desirable.

Aesthetically, the medial brow position should be lower than or at most at the level of the supraorbital rim. The eyebrow shape should have an arched appearance or an apex lateral slant.¹⁰ The most common configuration of the postsurgical brow lift is one of excessive elevation of the medial brow past the supraorbital rim.

Lateral Canthus

The effect of brow-midface techniques on the lateral canthus must be anticipated. Hairline endoscopic techniques that raise the midface may raise the lateral canthus. This canthal elevation can at times be desirable (i.e., when a postblepharoplasty round eye deformity or a depressed lateral canthus is present). However, the effect on the canthus should be anticipated preoperatively. Tension that raises the midface must traverse as a midpoint the lateral canthal region and exert an upward vector on this area. If the lateral canthus is in the correct position, a combined brow-midface technique may have an undesirable effect on the lateral brow, resulting in the appearance of a high lateral canthus.

Techniques aimed solely at elevation of the lateral brow (coronal brow lift, anterior hairline lifts, temporal lifts) do not generally affect the position of the lateral canthus. Such brow elevation techniques performed in a subperiosteal, subgaleal, and subcutaneous level generally do not have an impact on the position of the lateral canthus.

TREATMENT OF THE HAIRLINE

Preservation of the temporal, anterior, and sideburn hairline in women and of the temporal and anterior hairline in men is crucial. Performing a coronal lift in all patients is not acceptable because of the hairline destruction in many patients with high or receding hairlines.

Sideburn preservation in women is important. It can no longer be elevated with impunity during a coronal lift; this leaves the patient with an extended preauricular bald spot that is difficult to conceal and will never regrow. Many secondary procedures aim to reverse this deforming technique, with variable success. During a face lift procedure, the deformity can be avoided by excision of a triangle that typically comes to a point 2 cm in length along the inferior sideburn 2 cm from the ear, with a 7-mm pretragal distance at the base of the sideburn. In some patients with a high hairline, an anterior hairline technique or an endoscopic technique with fixation to the deep temporal fascia may be needed.

The temporal hairline should not be excessively mobilized posteriorly. This causes a vast hairless expanse and contributes greatly to the “windswept” look (Fig. 47-6). It may be necessary to balance a temporal lift (subcutaneous or subgaleal) with an upper lid blepharoplasty to achieve relief of upper lid blepharochalasis with lateral brow ptosis or to perform an anterior hairline procedure.

The surgeon should consider the height of the forehead. Already high foreheads should not be further elevated with a coronal lift. This causes a large, unattractive hairless forehead. It may be necessary to balance the degree of skin resection in the performance of a coronal lift with procedures targeted to the procerus, corrugator, superior orbicularis oculi fibers, and frontalis fibers. In patients with high frontal hairlines, an anterior hairline procedure or endoscopic procedure targeted to specific muscle groups is more appropriate. In the properly selected patient, botulinum toxin treatments are now a viable alternative to direct or indirect brow procedures.

Correction of the High Anterior Hairline

If further brow ptosis occurs in a patient who has excessive elevation of the anterior hairline, it may be advisable to perform a subcutaneous temporal brow lift. This procedure predictably restores some anterior

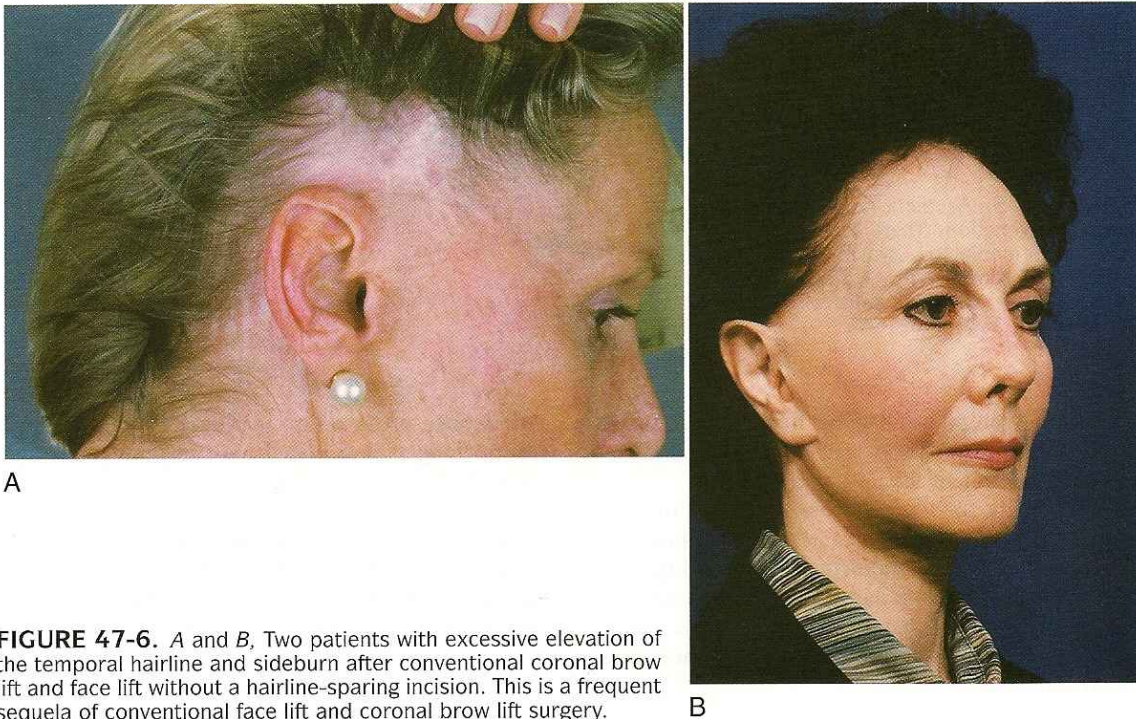


FIGURE 47-6. A and B, Two patients with excessive elevation of the temporal hairline and sideburn after conventional coronal brow lift and face lift without a hairline-sparing incision. This is a frequent sequela of conventional face lift and coronal brow lift surgery.

hairline; however, it does require an anterior hairline incision. This incision can be minimized if the randomness of the anterior hairline is followed with the incision. Selected temporal lifts in the widow's peak are effective at elevating the lateral brow with minimal scarring and no further destruction of the hairline. Subcutaneous or subgaleal anterior hairline brow lifts can selectively elevate the lateral brow without undesirable excessive central brow elevation.

Correction of Temporal Hair Loss

Excision of a triangle underneath the sideburn in the performance of a revisional face lift restores the sideburn to some extent. It may be necessary to perform Z-plasties or transposition of hair-bearing skin to correct a severely disturbed hairline. On occasion, hair transplantation with micrografts is necessary when excessively aggressive coronal lifts have been performed.¹¹ Various hair-bearing flaps can transpose hair-bearing skin into iatrogenic alopecic defects.¹²

Direction of Incision in Hairline

When a brow lift is performed within the hairline, there has been some debate about the best direction of the incision. Incisions perpendicular to the direction of exit of hair follicles may result in improved scarring;

however, the incision should be exactly parallel to the exiting direction of the hair shafts, preserving the delicate hair bulbs.¹³ Certainly, careful handling of the tissues, exact coaptation of the edges, judicious use of electrocautery around hair follicles, and care not to cut through the hair bulbs all contribute to finer scars.

Ear Incisions

It may be preferable in all women except those with the lowest sideburns to preserve the sideburn by making an incision at the base of the sideburn rather than elevating the hairline superiorly. The incision should closely approximate the anterior ear. The tragus should redrape easily and have a slight anterior hollow and not be pulled forward. The earlobe should be anchored in such a fashion as not to cause a pulled or "pixie" ear deformity. Posterior auricular incisions are best made into and not along the hairline. The posterior hairline should match after elevation of the neck flap without a surgically made step-off.

FOREHEAD AND BROW LIFTS

The primary goal in brow rejuvenation surgery is to correct the signs of aging in the brow, temple, and periorbital areas. Infrabrow hooding, decrease in the

vertical dimension of the orbital aperture, and upper blepharochalasis occur with advancing age. Many signs of aging occur in the periorbital and temple area as well (see Table 47-1).

The efficacy of traditional versus endoscopic brow lifts has been debated. In either case, brow ptosis is likely to recur during a period of years. One year post-operatively, there may be no difference in standard anthropometric sites including brow, medial canthus, and subnasale. Pretrichial or coronal lifts may relax so that at 5-year follow-up, little residual brow elevation may be present. Some authors have found that there is little longevity of conventional coronal lifts compared with endoscopic subperiosteal lifts.¹⁴

Direct Minimally Invasive Brow Lift Rejuvenation Procedures

Selective brow analysis should lead the surgeon to perform tailored operations combining a number of accepted techniques in a customized fashion. Endoscopic or direct myomectomy can be performed in patients who do not wish to have repeated botulinum toxin injections. This procedure, involving a debulking or complete removal of glabellar musculature, can be performed through an endoscope with hairline entry incisions. Alternatively, the same procedure can be performed through an upper blepharoplasty incision or stab incision in or just below the medial brow. The muscles targeted are the procerus, corrugator, frontalis, and medial fibers of the orbicularis oculi muscle. The extent of dissection is generally a region 1.5 cm lateral to the midline, onto the radix, and upward by 2 cm. This avoids the neurovascular bundle and main branches of the supratrochlear nerves.

The effect of this procedure can be predicted by remembering the functions of the individual forehead muscles. The corrugator depresses the brow and brings it centrally, as do orbital fibers of the orbicularis oculi. Procerus fibers depress the central brow. Therefore, after the procedure, the interbrow distance increases and some central elevation of the brow is noted. Glabellar and procerus furrows are reduced. Frowning is not eliminated; a frown can still be generated from frontalis and orbicularis fibers above the medial and lateral brow.

Muscle Division Techniques

Techniques that involve division of forehead muscles usually work only temporarily. In general, muscle function returns as small nerve fibers and muscle regenerate. This includes division of glabellar musculature and superselective ablation of frontal nerve branches destined for the glabellar musculature. Most clinicians have found that transection alone of corrugators is at best a temporary solution.

Nerve Ablation Techniques

Nerves to the corrugators can be ablated selectively in a transcutaneous procedure wherein external neurostimulators isolate the locus of the end nerve. In this way, individual nerves to the corrugators or orbital portion of the orbicularis muscle causing frown lines or glabellar furrowing can be ablated. Absolute alcohol is then injected into this locus.

Because end nerves regenerate, this technique seems to be short-lived. Perhaps the neurostimulator is detecting muscle activity rather than end nerves, and the damaged muscle fibers from the absolute alcohol regenerate or heal.

Single-Stitch Techniques

One hallmark of all standard techniques is that undermining is done in a relatively wide plane of the tissues to be elevated. Historically, single-stitch techniques (i.e., the "marionette" stitch) have been described that purport to elevate tissues by a single suspension-type stitch with minimal or no undermining. These techniques have not gained wide acceptance and may suffer from two potential problems. First, the stitch may break or pull loose, rendering the operation ineffective. Second, the tension may be directed to a small segment of tissue, and the pull may not elevate the adjacent tissues, resulting in visible lines of pull. If the stigmata of aging in a patient were isolated to a single locus, a single stitch might remedy this focal aging. Most patients, however, age over a broad plane and benefit from broad undermining and elevation, a concept that all current tissue elevation techniques espouse.

Coronal Brow Lift

The face lift incision is extended cephalad approximately 5 cm from the anterior hairline around to the contralateral ear. Dissection proceeds at a subgaleal level until 5 cm above the supraorbital rim, where the dissection then traverses to the subperiosteal plane. This allows preservation of the supraorbital and supratrochlear nerve bundles. Glabellar musculature and transverse frontalis lines can be dealt with by direct excision. Dissection onto the glabella and release of lateral superior orbital ligaments facilitate upward rotation of the flap. A segment of hair-bearing skin is then removed, tailored to the needed degree of brow elevation desired. The coronal lift will alter the hairline, and this change should be projected and weighed against less invasive forehead treatments.

The coronal lift achieves predictable, long-lasting elevation of the brows and significant reduction in glabellar and transverse frontalis rhytids. It is technically easy, provided one avoids the frontal branch in the lateral forehead flaps.

There are several disadvantages to the coronal lift. Dysesthesias with long-lasting or permanent numbness can occur around the long coronal incision. If it is overdone, the coronal lift can produce excessive elevation of the brow, especially the central brow, and lead to a surprised appearance. Often, permanent alterations of the hairline occur. Medial elevation of the brow translates directly to loss of anterior hairline and an elevation in the forehead height. The lateral brow elevation translates to a commensurate loss of temporal hairline. In combination with a traditional face lift in which the sideburn is raised, there can be considerable loss of temporal and sideburn hair, potentially leading to a windswept, bald appearance. If excessive hair-bearing skin is resected and the incision is closed under tension, large areas of alopecia can result.

Upper Eyelid Blepharochalasis

Patients with upper lid blepharochalasis and brow ptosis represent a challenge. It is often best to perform the brow elevation technique first. This will allow the surgeon to avoid an unexpected lagophthalmos when the blepharoplasty is then performed. Dry eye syndrome and excessive corneal exposure can occur if excessive resection from a blepharoplasty is exacerbated by simultaneous brow elevation. Some surgeons advocate having patients awake during the performance of these procedures. Others advise staging brow and upper eyelid rejuvenation.¹⁵ Upper blepharoplasty does not appear to change brow position.¹⁶

Male Brow Surgery

The frequency of male plastic surgery is increasing. Endoscopic brow surgery may be appropriate for men with male pattern balding. Endoscopic surgical approaches may minimize the incidence of visible scars in patients with receding hairlines, hair transplants, or baldness.

Care must be taken not to elevate either the medial or the lateral brow excessively. This may produce an overly feminized appearance. Rather than having an arched lateral brow in men, a flat or mildly descending brow may be more aesthetically appealing. A subcutaneous lateral brow lift and an extended upper blepharoplasty will often suffice to rejuvenate the periorbital and brow area in men without feminization characteristic of overaggressive brow lifts (Fig. 47-7).

Especially in men, the effect of forehead or midface lifting on the temporal and sideburn hairline must be discussed preoperatively. If a retrotragal face lift is performed, the sideburn may move laterally, obscuring the normal hairless landmark between the tragus and the beginning of the sideburn. In some patients, the length of the sideburn is limited. Therefore,

sideburn elevation with lateral brow lifts or the superior portion of the rhytidectomy may obliterate the sideburn. This can be avoided if a Burow triangle is excised below the sideburn during elevation of the facial flap.

Considerable upper facial rejuvenation can be accomplished through an upper blepharoplasty incision alone.¹⁷ Dissection encompasses the superior orbital rim. Soft tissues are elevated. Resection of the procerus and corrugator muscles is accomplished through the blepharoplasty incision. Typically, brow tissues are elevated and secured to temporal fascia and periosteum of the orbital rim. The frontotemporal flap can be anchored with percutaneous screws or contouring tape.

Endoscopic Brow Lift

A thorough knowledge of the fascial layers of the temple and the ligamentous attachments of the upper face and midface along with a working knowledge of the anatomy of the brow, temple area, and upper face is essential for surgeons performing endoscopic brow and facial surgery (Figs. 47-8 to 47-11). Younger patients who are disinclined to have repeated botulinum toxin injections or men with male pattern baldness are well suited for the endoscopic approach to facial and brow rejuvenation. Patients who already have higher foreheads of relatively high or sparse temporal hair patterns may also be good candidates.¹⁸ In addition, the endoscopic brow lift may benefit patients suffering from unilateral frontal branch palsy with ptosis.¹⁹ Acceptance by patients of endoscopic forehead lifts may be higher than that of long incision techniques.

Coronal lifts are often compared with endoscopic lifts of the forehead. Endoscopic lifts involve elevation at a subperiosteal level of tissue above the zygoma, with elevation of the zygomaticus major and minor muscles, the levator anguli, and portions of the orbicularis oris muscles. This dissection is connected with a dissection in the temple area carried out above the deep temporal fascia. The temple area can be accessed through temporal or lateral hairline incisions or, in some cases, with a larger incision over the lateral temporal region.

For two reasons, the difficult portion of the dissection is the transition from the intermediate temporal fascia to the subperiosteal plane at the zygoma. First, the frontal branch of the facial nerve runs supraperiosteally from the tragus of the ear to a position 1.5 cm lateral to the lateral brow. This can be injured if the dissection is not strictly subperiosteal over the zygoma or if undue traction is placed on this relatively inflexible layer. Second, the transition from the deep temporal fascia to the zygomatic subperiosteal

Text continued on p. 229

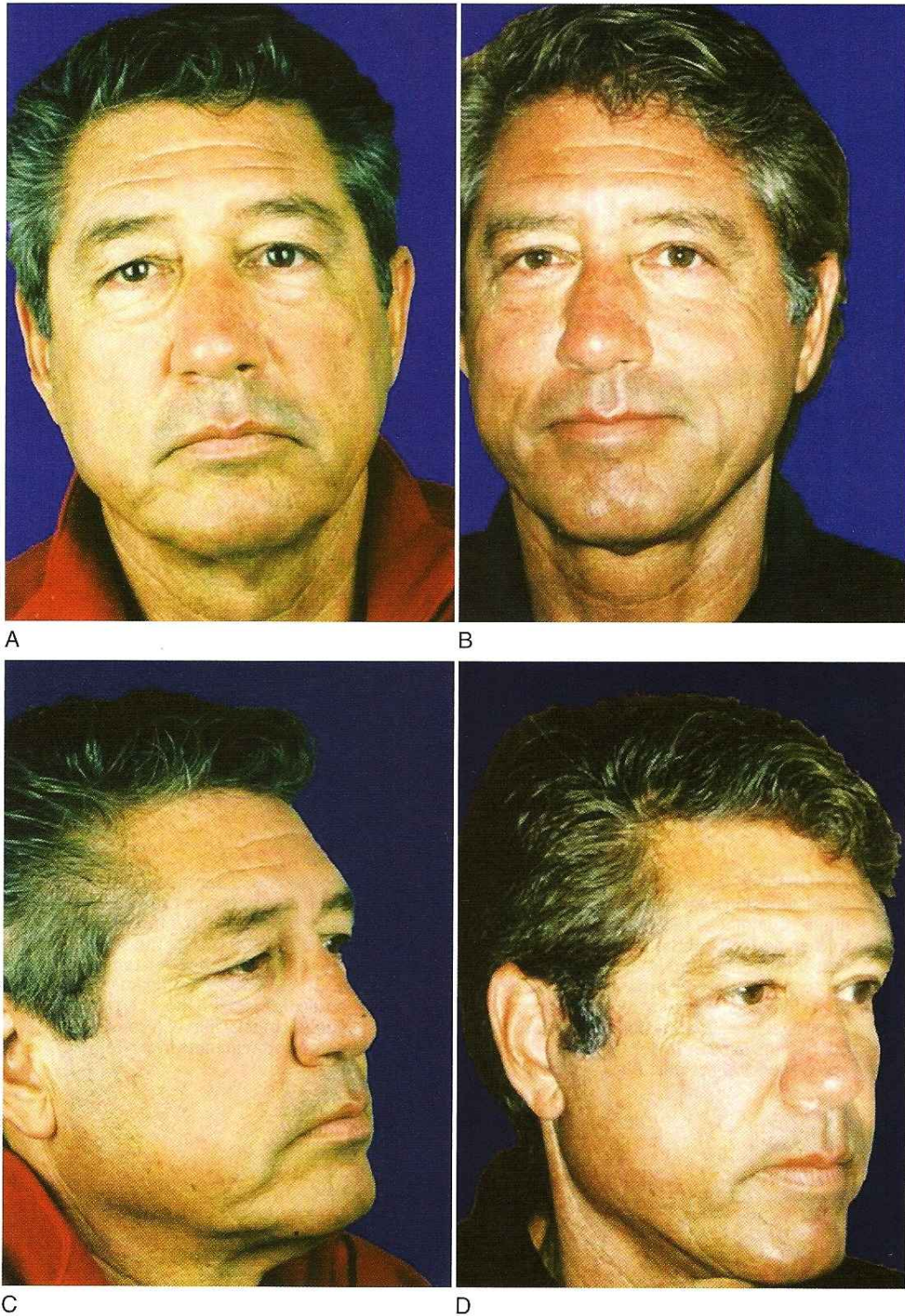


FIGURE 47-7. *A* and *C*, Preoperative views of a man with aging face, eyes, midface, and brows. *B* and *D*, Postoperative views after face lift, cheek lift, extended upper blepharoplasty, and subtle lateral temporal brow lift. An extended upper blepharoplasty combined with a lateral brow lift results in minimal distortion of the temporal hairline yet offers adequate rejuvenation without the feminization associated with excessive brow lifting procedures in many male patients.

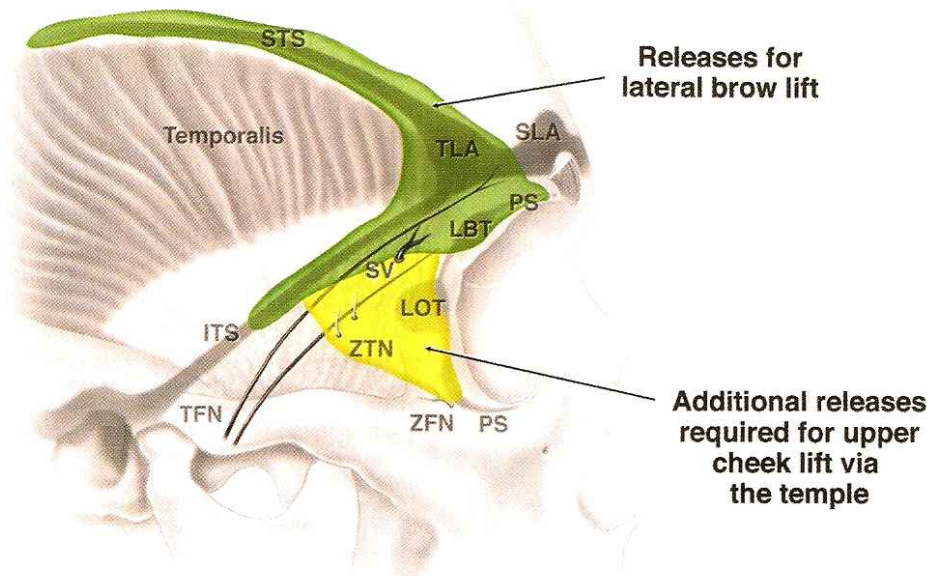


FIGURE 47-8. Additional release of the inferior and superior temporal septa and the temporal adhesion may be necessary to elevate the lateral brow area in endoscopic brow lift technique. If midfacial tissue is also elevated, it may be necessary to release the lateral orbital thickening (LOT) of the septum and spare the zygomaticotemporal nerve (ZTN). The sentinel vessel (SV) is located laterally and superiorly at the outer orbital rim. ITS, inferior temporal septum; LBT, lateral brow thickening of periorbital septum; SLA, supraorbital ligamentous adhesion; STS, superior temporal septum; TFN, temporal branch of facial nerve; TLA, temporal ligamentous adhesion; PS, periorbital septum; ZFN, zygomaticofacial nerve. (From Moss CJ, Mendelson BC, Taylor GI: Surgical anatomy of the ligamentous attachments in the temple and periorbital regions. *Plast Reconstr Surg* 2000;105:1477.)

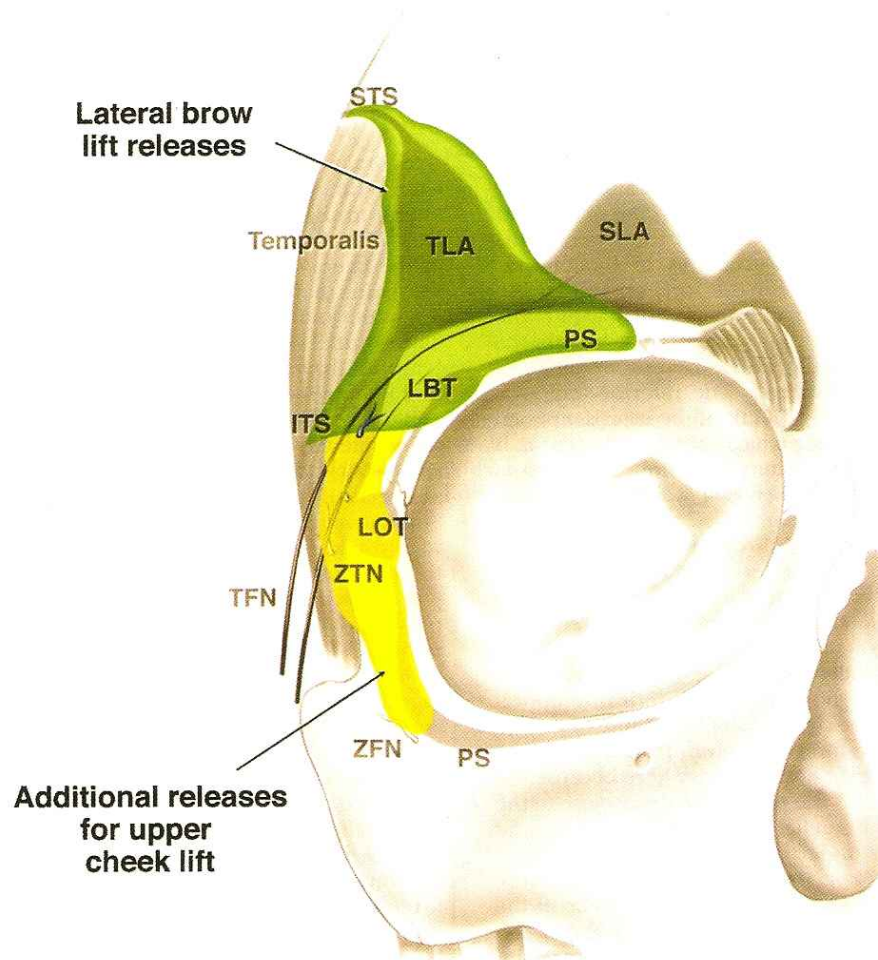


FIGURE 47-9. Anterior view of area to be released in performance of endoscopic lateral brow lift, including periorbital septum (PS), lateral brow thickening of periorbital septum (LBT), and inferior temporal septum (ITS). Cheek elevation may require additional elevation of the lateral orbital region. LOT, lateral orbital thickening of septum; SLA, supraorbital ligamentous adhesion; STS, superior temporal septum; TFN, temporal branch of facial nerve; TLA, temporal ligamentous adhesion; ZFN, zygomaticofacial nerve; ZTN, zygomaticotemporal nerve. (From Moss CJ, Mendelson BC, Taylor GI: Surgical anatomy of the ligamentous attachments in the temple and periorbital regions. *Plast Reconstr Surg* 2000;105:1477.)

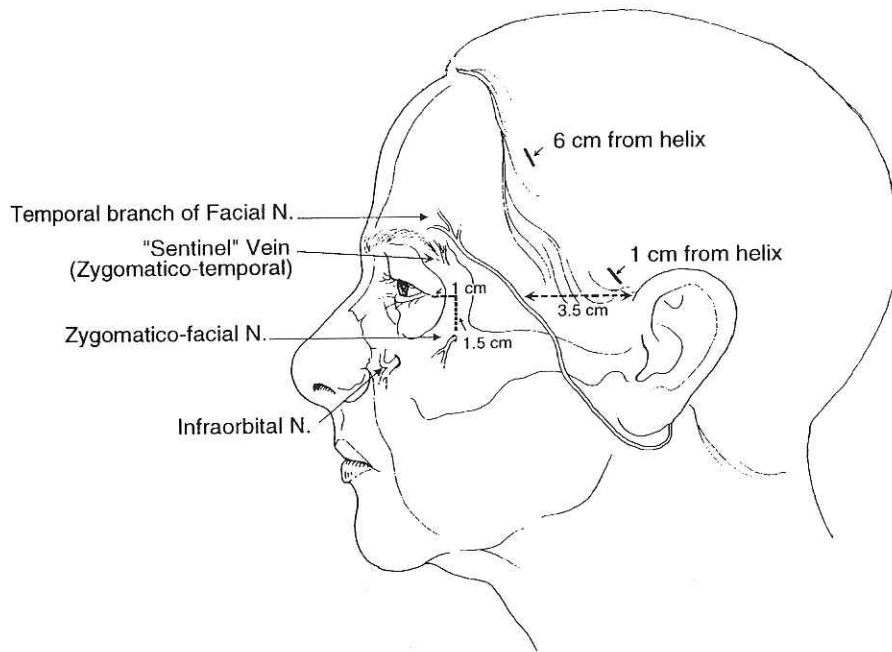


FIGURE 47-10. Hairline incisions from endoscopic brow lift with nerves delineated, lateral view. Note typical location of incisions. Particularly note the course of the frontal branch of the facial nerve. (From Anderson RD, Lo MW: Endoscopic malar/midface suspension procedure. *Plast Reconstr Surg* 1998;102:2196.)

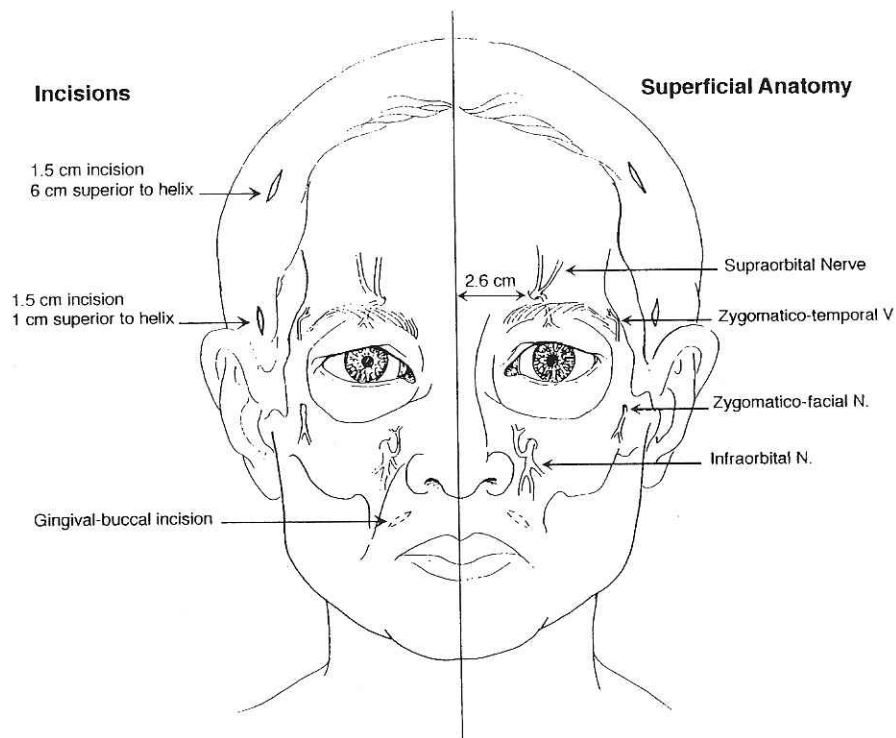


FIGURE 47-11. Nerves to be avoided in the course of subperiosteal undermining for the endoscopic face lift. (From Anderson RD, Lo MW: Endoscopic malar/midface suspension procedure. *Plast Reconstr Surg* 1998;102:2196.)

plane involves transition over the temporal fat pad. If this is injured, a hollow appearance in the temple can result unilaterally or bilaterally.

In this dissection, an intraoral approach is helpful. Through an upper buccal sulcus incision (avoiding the buccal fat pad), a subperiosteal plane is developed. This is relatively easy up to the level of the zygoma. Many surgeons then make the transition either from the superior dissection or through a separate lateral incision over the zygoma itself, where a subperiosteal dissection is easily performed. The lower and upper dissection planes can then be connected at the intermediate temporal fascia (Fig. 47-12). Care is taken not to injure the zygomaticotemporal, supraorbital, zygomaticofacial, and infraorbital nerves (see Fig. 47-11) in the course of the subperiosteal dissection.

In general, three hairline incisions allow insertion of the endoscope and instruments (Figs. 47-13 and 47-14). The forehead flap is undermined endoscopically, and the glabellar muscles are avulsed or cut directly under endoscopic guidance. The lateral superior orbital ligaments are released to allow upward rotation of the forehead flap. Anchoring is performed to the posterior scalp, to biodegradable pins, or to anchor

screws placed in the scalp. Temporary posts are removed after sufficient time to allow the periosteum to adhere to its new position.¹⁶ Periosteal adherence is believed to occur within 12 weeks postoperatively. Until that time, depressor mimetic muscle function counteracts the effect of superior advancement of the subperiosteal flap. Depressor muscles include the procerus, medial fibers of the orbicularis muscle, and corrugator fibers. It may be beneficial to use botulinum toxin during the healing phase of an endoscopic brow lift to reduce the undesirable depressor function.²⁰ Botulinum toxin, applied to glabellar musculature, can reduce the downward force of depressor mimetic muscles that can reverse the advancement of the subperiosteal flap in endoscopic brow surgery. The frontalis muscle can then function unopposed to elevate the brow. Midfacial suspension sutures can help anchor the subperiosteal flap in place while midfacial and upper facial tissues are elevated (Figs. 47-15 and 47-16).

Long-term elevation has been noted in these patients. It is often thought that brow position falls more quickly after endoscopic lifts than with traditional skin excision-type brow lifts. With more extensive mobilization and midfacial and upper facial resuspension, this may no longer be true. Hairline

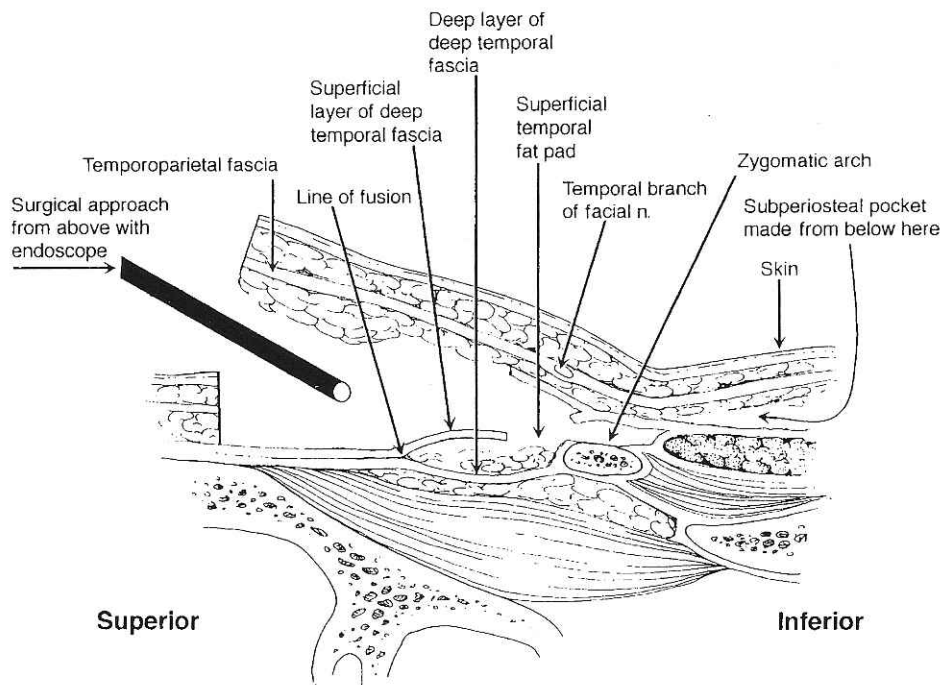


FIGURE 47-12. Endoscopic dissection in the transition area from the temple to the zygomatic periosteum. The intermediate temporal fascia is opened. If this dissection occurs in the midportion of the zygoma, there will be a direct transition from the temporal fat pad into the zygoma, with no transitional fascial layer. Damage to the temporal fat pad should be avoided to prevent excessive temporal hollowing. (From Anderson RD, Lo MW: Endoscopic malar/midface suspension procedure. *Plast Reconstr Surg* 1998;102:2196.)

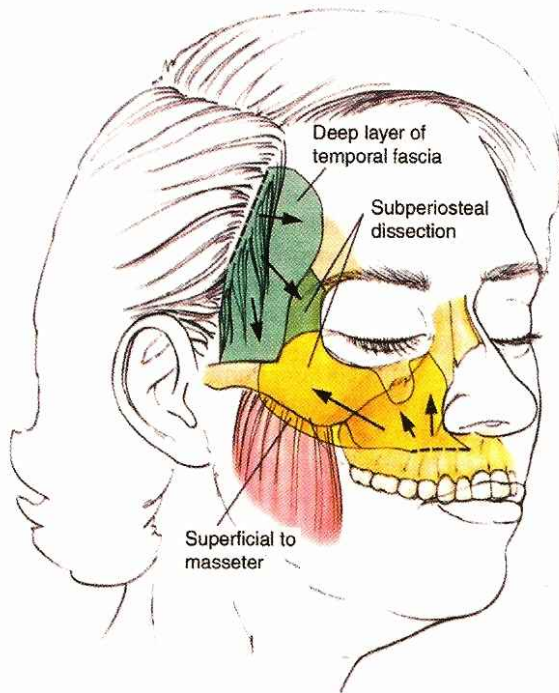


FIGURE 47-13. Levels of dissection in the endoscopic upper face-midface lift. A subperiosteal dissection over the midface and zygoma is combined with a dissection on the deep temporal fascia from above. The transition point in this dissection is at the temporal fat pad in the lower temple, just above the zygoma. (From Paul MD: Morphologic and gender considerations in midface rejuvenation. *Aesthetic Surg J* 2001;21:349.)

preservation is also generally superior in endoscopic versus traditional coronal incisions.

More extensive release of ligamentous structures plus undermining at a subperiosteal level (below the innervation) of the orbicularis oculi may improve brow tail elevation in the upper midface. This may allow superior elevation of the cheek pad-temple complex.²¹

FIXATION

Once mobilization of the brow and disinsertion of the superior orbital rim attachments have been accomplished, fixation should elevate the brow and hold it in a more superior position. Numerous methods for fixation of the brow have been described, including K-wire fixation transcutaneously, flexible tape on the forehead, absorbable and nonabsorbable screws, and no fixation at all (allowing unopposed frontalis pull to elevate the brows).

MUSCLE RESECTION

Specific rhytids can be marked externally and resected endoscopically. This can include fibers of procerus,

superior orbicularis oculi, corrugator, and frontalis muscles. Predictably, resection of these muscles is as important as consideration of the degree of brow elevation.

LONGEVITY

Physicians using the endoscopic approach have noted greater elevation of the brow over time than in those patients who have undergone coronal brow lifts. In particular, there was a persistent elevation of 7 mm in the vertical height of the midpupillary brow 1 year after the operation. In one cadaver study, no difference in forehead elevation was noted between differing techniques, including subperiosteal dissection to the superior orbital rim, subperiosteal dissection with release of the periosteum, and subgaleal dissection. Rather, all techniques accomplished an elevation off the brow.^{16,22}

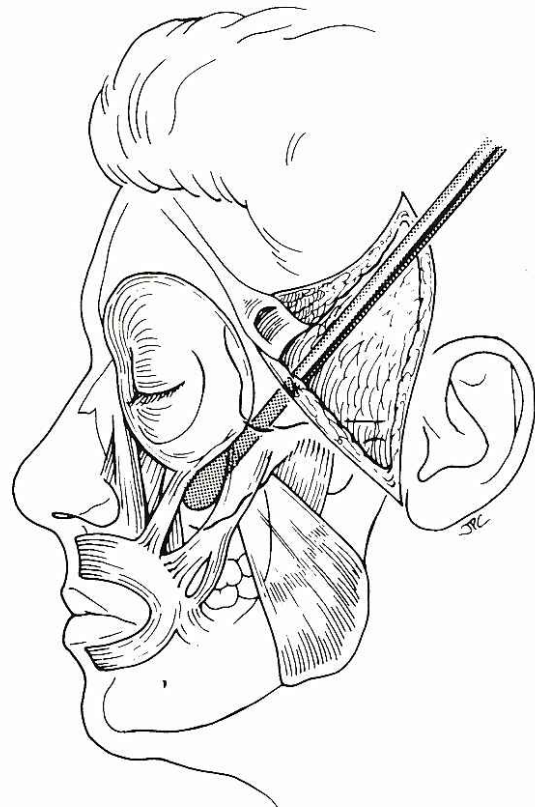


FIGURE 47-14. Combined subperiosteal technique with a lateral temporal incision is characteristic of the many mixed open endoscopic techniques. (From Finger ER: A 5-year study of the transmalar subperiosteal midface lift with minimal skin and superficial musculoaponeurotic system dissection: a durable, natural-appearing lift with less surgery and recovery time. *Plast Reconstr Surg* 2001;107:1273.)

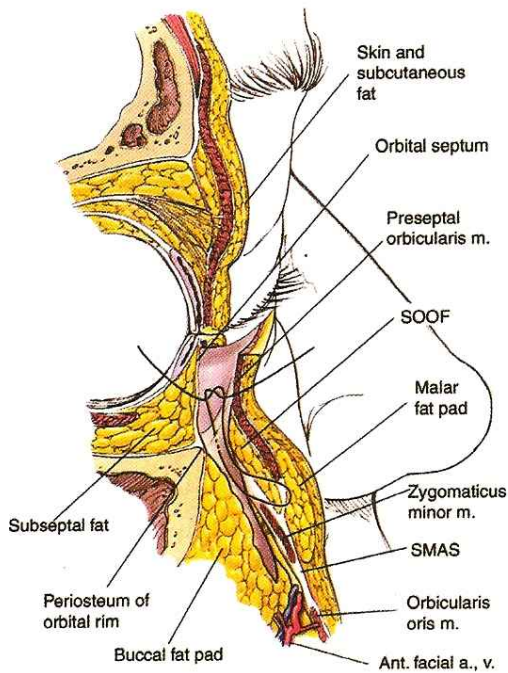


FIGURE 47-15. Lateral view of the anchoring of the midface and upper face. There are three common anchoring sites: the inferior orbital rim and the temple, the intermediate temporal fascia, and the deep temporal fascia. Of these sites, the intermediate temporal fascia or deep temporal fascia may provide greater purchase and easier elevation of the facial flap. This technique incorporates a midfacial elevation at the suborbicularis level over the zygomatic muscles using the orbicularis, suborbicularis oculi fat (SOOF), and malar fat pad. (From Paul MD: Morphologic and gender considerations in midface rejuvenation. *Aesthetic Surg J* 2001;21:349.)

DISADVANTAGES

The anatomic transitions around the temple and the retaining ligaments of the cheek present unique challenges in endoscopic surgery. In particular, extensive dissection above the zygomaticus major may weaken orbicularis oculi nerve fibers.²³ Patients can have hair growth problems at the cannula insertion sites that can be significant and permanent. Care must be taken not to torque the cannulas and endoscopic equipment excessively against the insertion sites, lest alopecic or scarred areas develop. Patients should be cautioned that cannula insertion sites could be visible either temporarily or permanently. Many surgeons believe that the results of endoscopic brow lifts are more temporary than those of coronal lifts. Bunching of the skin at the hairline can occur. In general, this is temporary and adjusts without any fall in the anterior hairline in the short term. Endoscopic forehead surgery can also lead to a loss of temporal fat pads, causing a temporal hollowing.

Temporal Lift

Lateral brow ptosis can be corrected with a lateral subcutaneous brow lift. This can be combined with inter-brow muscle resection. A triangular section of balding skin is excised at an anterior hairline location, and a subcutaneous dissection is performed.²⁴ This technique can partially correct an excessively raised or high natural hairline at the level of the lateral frontal forehead.

Nerve damage of any sort is rare. Elevation of the lateral brow is predictable and safe, with the proviso that there will be an anterior hairline incision. This lateral brow lift has been combined with a medial corrugator resection. The supraorbital and supratrochlear neurovascular bundle is almost never encountered more medial than 1.6 cm lateral to the midline. Therefore, a blind resection encompassing 1.5 cm lateral to the midline predictably avoids the supratrochlear neurovascular bundle.^{24,25}

These minimally invasive techniques have particular use when previous excessive hairline elevation is present and in the thinning widow's peak area in older women. These so-called trichophytic incisional approaches to the upper brow are a valuable tool in revisional facial rejuvenation surgery.²⁶

Brow Lowering Techniques

Patients with iatrogenic excessive lateral or central hairline elevation who now require either correction of

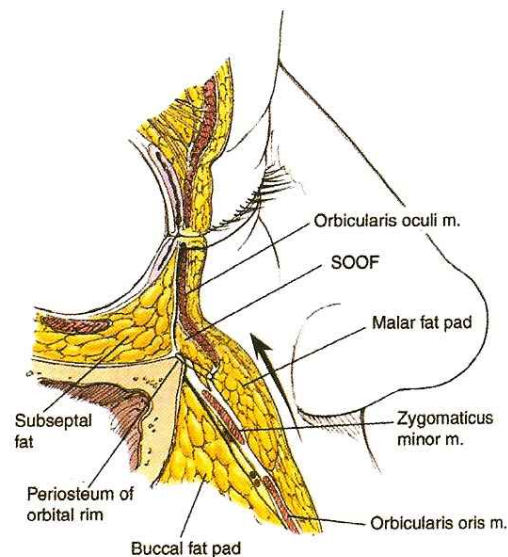


FIGURE 47-16. Elevated subperiosteal flap in mid-upper facial rejuvenation, side view. SOOF, suborbicularis oculi fat. (From Paul MD: Morphologic and gender considerations in midface rejuvenation. *Aesthetic Surg J* 2001;21:349.)

the hairline or further brow surgery may benefit from anterior hairline incisions or endoscopic surgery. The endoscopic approach with midfacial and temporal mobilization may be used to reduce the effects of excessively elevated hairlines from previous coronal brow lifting or overaggressively elevated endoscopic brow surgeries.²¹

Other techniques have been developed to lower an excessively high forehead. These include re-creating the coronal incision and releasing any fixation sutures from an endoscopic brow lift or from serial galeal scoring with dressing fixation of the forehead in a lower position. Excessive brow elevation caused iatrogenically may result in chronic dry eye syndrome, corneal exposure with exposure keratopathy, and persistent lagophthalmos.

Botulinum Toxin

Botulinum toxin now deserves a separate section in the discussion of brow rejuvenation. It is important to understand how botulinum toxin affects the forehead musculature and the interrelated dynamics of forehead muscle pull of each of the muscle groups. Plastic and reconstructive surgeons are uniquely suited to perform botulinum toxin injection because they are familiar with individual muscle roles on the forehead as a whole.

The mean midpupillary brow elevation from glabellar Botox injection is 1 mm. The average lateral brow elevation after selective injection of brow depressors laterally is 4.8 mm.²⁷ These temporary results are comparable to those of published series of successful brow lifting procedures. Botox now assumes a more prominent role as a temporizing treatment for patients not yet ready for surgery, especially younger patients.

The effect of botulinum toxin can be predicted by remembering the functions of the individual forehead muscles. The corrugator acts to depress the brow and bring it centrally. The frontalis muscle can assist in medial positioning of the brow. Therefore, with glabellar Botox injection, the interbrow distance increases and some central elevation of the brow is noted. Glabellar and procerus furrows are reduced. Frowning is not eliminated because a frown can still be generated from frontalis and orbicularis fibers above the medial and lateral brow.

Botulinum toxin can be applied selectively to lateral frontalis rhytids. This may produce a brow ptosis in older patients because the tonic brow elevation of the frontalis muscle is cancelled.

Selective application to the upper orbicularis fibers (which act to depress the brow) results in slight elevation of the lateral brow. Care must be taken not to inject the levator mechanism of the upper eyelid when this maneuver is performed.

Presently, it is inadvisable to use botulinum toxin on the crow's-feet region of the orbicularis oculi muscle when a midface lift is undertaken, usually for 3 to 6 months, depending on the state of the lower eyelid tonicity. Temporary hypotonicity of the lower lid can result.

Laser Resurfacing

Carbon dioxide or erbium:yttrium-aluminum-garnet laser resurfacing can be performed in most patients at the same setting as subperiosteal or subgaleal brow lifts. It is not recommended to resurface the actual incision in anterior hairline brow lifts. Similarly, most midfacial rejuvenation procedures can safely be combined with laser resurfacing, as can brow rejuvenation procedures (Fig. 47-17).²⁸ Small series have described simultaneous carbon dioxide laser resurfacing with subperiosteal face lifts for the upper and middle thirds of the face; caution should be exerted before laser resurfacing is performed over undermined flaps.²⁹ Perhaps there is more safety in performing full-face carbon dioxide laser resurfacing with an endoscopic lift than with a conventional face lift.³⁰

MIDFACIAL AGING

There are many components to midfacial aging. Lower eyelid fat herniations develop. A prominent nasojugal groove and infraorbital hollow develop as the cheek pad complex descends (Fig. 47-18). Laxity of the lateral canthal ligament results in horizontal lid laxity. Orbicularis droop with relaxation of the orbicularis oculi muscle can contribute to festoon formation and descent of the cheek pad complex. Subcutaneous fat atrophy causes facial volume loss. Upper eyelid blepharochalasis and lateral brow hooding develop. Nasolabial fold depth and heaviness above the nasolabial fold result from midfacial droop and midfacial fat atrophy.

Arcus Marginalis Release

This innovative technique allows distribution of unwanted fat herniation from infraorbital fat bulges down into the infraorbital hollow (Fig. 47-19). The effect is reduction of infraorbital hollowness. This camouflage technique is useful not only as a primary technique but also as an adjunct for midfacial advancement techniques. In many patients with thin skin, the lower eyelid bulge does not seem to be effectively effaced. In such patients, it may be preferable to remove the fat completely from underneath the orbital septum and to replace it as a free (untraumatized) fat graft into the nasojugal groove and infraorbital hollow. Nevertheless, this technique was critical in the evolution

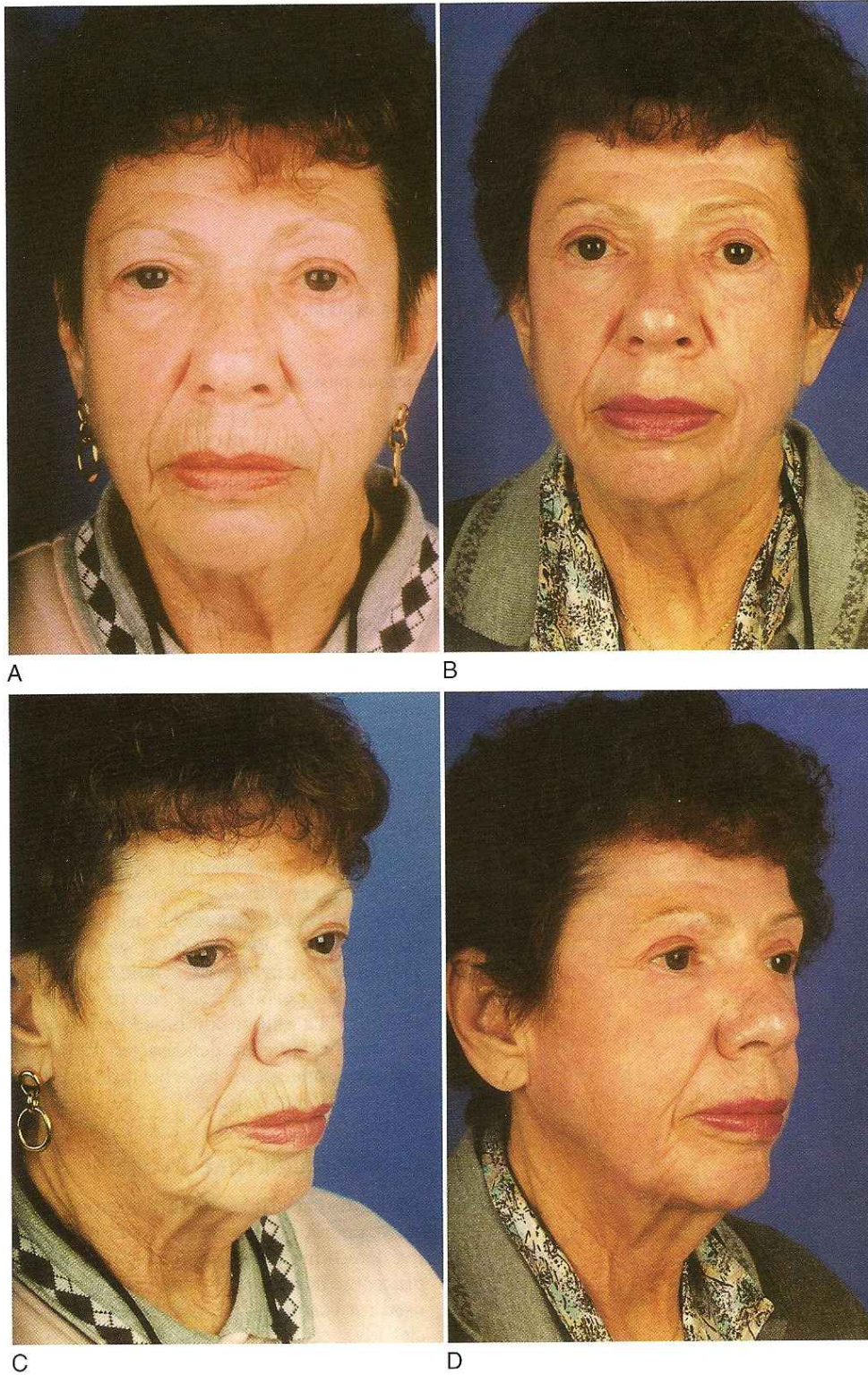

FIGURE 47-17. *A* and *C*, Preoperative views of a patient troubled by periorbital aging and lip rhytids. *B* and *D*, Postoperative views after full-face carbon dioxide laser resurfacing, upper blepharoplasty, and midface elevation. Additional brow surgery would have resulted in excessive brow elevation. The patient did not desire neck rejuvenation.

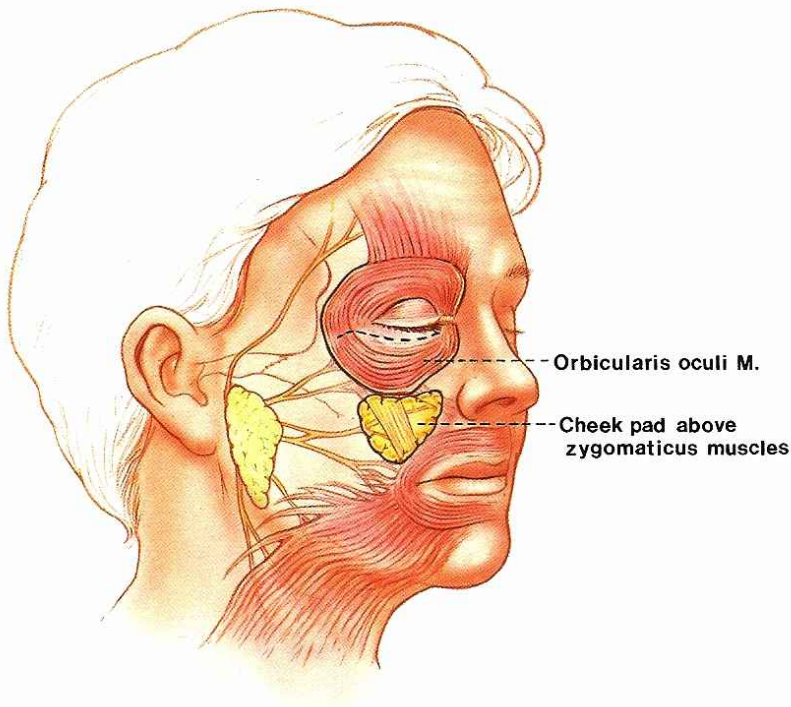


FIGURE 47-18. Ptosis of the orbicularis muscle, the cheek pad complex, and the malar fat pad deepens the nasolabial fold. Descent of the malar fat pad leaves the infraorbital rim exposed. (From Moelleken B: The superficial subciliary cheeklift, a technique for rejuvenating the infraorbital region and nasojugal groove: a clinical series of 71 patients. *Plast Reconstr Surg* 1999;104:1863.)

of the concept of fat preservation rather than fat removal from the periorbital area.

Malar Fat Pad Elevation

Owsley³¹ advocated elevation of the malar fat pad in a superolateral vector during a face lift (Fig. 47-20). Nicoletis³² also recognized the necessity of elevation of the midface as well as of the side and lower portions

of the face. Both surgeons recognized the role of the malar fat pad in midfacial aging and heaviness of the nasolabial fold.

Redraping the Orbicularis Arc

For treatment of lower lid ectropion or to produce midfacial smoothness, McCord et al³³ described redraping of the orbicularis arc with a lateral canthoplasty and bone fixation (Figs. 47-21 and 47-22). The procedure involves drill hole fixation through the superolateral orbital bony rim to anchor the lateral canthus. This can be combined with spacer implants for middle lamellar deficiencies. Other orbicularis redraping operations have been proposed by Fogli,³⁴ Hinderer,³⁵ and Trepsat.³⁶

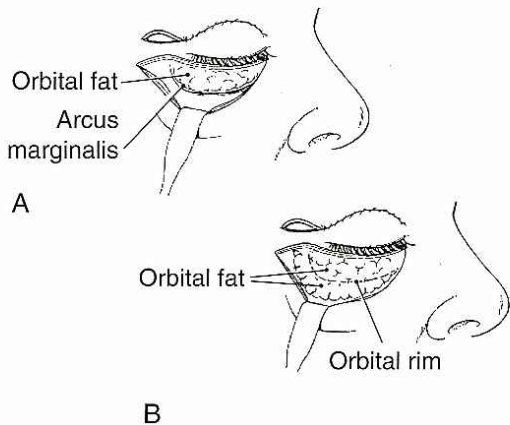


FIGURE 47-19. The insertion of the orbital septum onto the inferior orbital rim is the arcus marginalis. (From Hamra ST: Arcus marginalis release and orbital fat preservation in midface rejuvenation. *Plast Reconstr Surg* 1995;96:354.)

Cervicofacial Hike Procedure

The cervicofacial hike and similar procedures are innovative operations for reconstruction of large extirpative defects in the infraorbital region (Fig. 47-23). This procedure incorporates elements that are subsequently used for cosmetic purposes in temporal and midfacial advancement procedures.^{37,38}

Subperiosteal Face Lift Techniques

The subperiosteal approach to a face lift may have special merit in younger patients or patients with

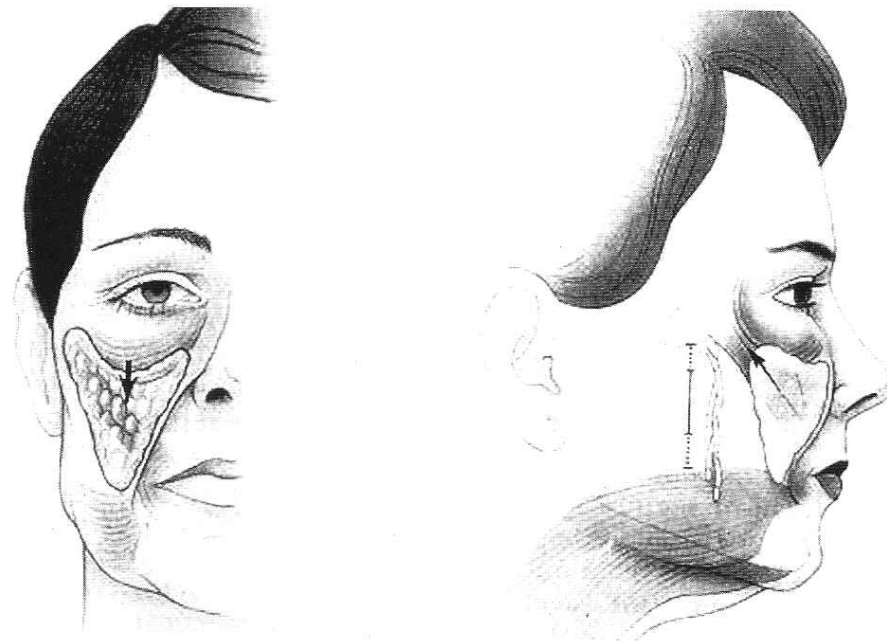


FIGURE 47-20. Direct elevation of the malar fat pad during a face lift. (From Owsley JQ: Lifting the malar fat pad. *Plast Reconstr Surg* 1993;91:463.)

FIGURE 47-21. Redraping of the orbicularis arc. The orbicularis muscle has a key role in midfacial elevation, suborbicularis dissection, and lateral canthal support. SOOF, suborbicularis oculi fat. (From McCord CD, Codner MA, Hester TR: Redraping the inferior orbicularis arc. *Plast Reconstr Surg* 1998;102:2471.)

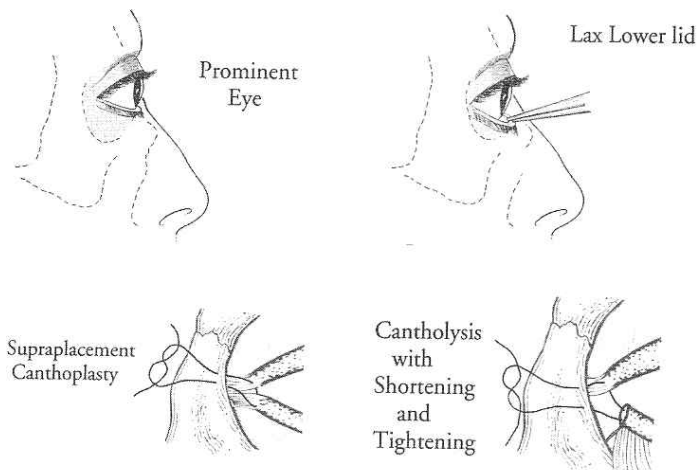
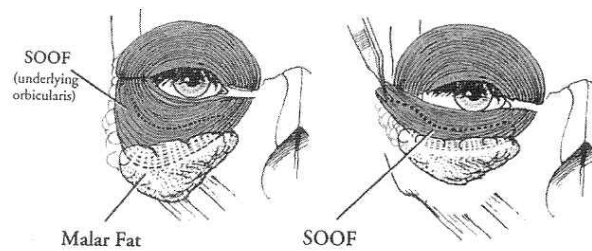


FIGURE 47-22. Lateral canthal support for a patient with lower eyelid laxity. (From McCord CD, Codner MA, Hester TR: Redraping the inferior orbicularis arc. *Plast Reconstr Surg* 1998;102:2471.)

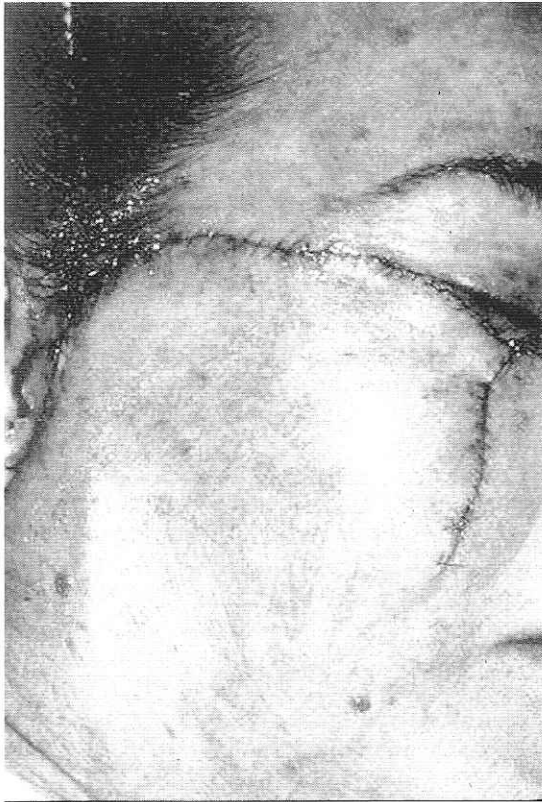

FIGURE 47-23. The cervicofacial hike is a reconstructive procedure for cheek defects. It involves elevation and fixation of mid and upper facial tissues. (From Longaker MT, Glat PM, Zide B: Deep-plane cervicofacial “hike”: anatomic basis with dog-ear blepharoplasty. *Plast Reconstr Surg* 1997;99:16.)

preferential upper face and midface ptosis with minimal neck ptosis. With the exception of the transition from the temple to the zygomatic periosteum, the dissection is straightforward. There may be advantages to endoscopic techniques because they do not disrupt blood supply to the extent associated with extended subcutaneous dissection. Therefore, there may be a greater margin of safety in combining full-face laser resurfacing with endoscopic temple and face lifts than with conventional face lifts.³⁰

An undesirable consequence of the subperiosteal face lift remains a potential injury to the frontal branch of the facial nerve. An extensive subperiosteal dissection may also result in significant postoperative swelling.

A temporal incision through endoscopic stab incisions or a longer nonendoscopic temporal incision is made. A second gingivobuccal sulcus incision or subciliary incision is then made. Mobilization of the tissues at the subperiosteal level occurs, with care taken around the zygoma to avoid frontal branch injury.³⁹ A posterior approach to the zygoma at the level of the tragus

may reduce the risk of frontal branch injury when soft tissues are mobilized off the zygoma. A posterior approach to the zygoma may lessen the incidence of nerve injury. This approach is straightforward, along the subperiosteal surface of the zygoma from lateral to medial. However, with experience, most practitioners find the subperiosteal technique to have a low incidence of temporary or permanent nerve injury.⁹ The maxilla, periorbital areas, and zygomatic areas are dissected at a subperiosteal layer, generally through a gingivobuccal sulcus incision or a subciliary incision. A Cottle elevator is used to sweep superiorly and inferiorly, and then the anterior and posterior dissections complete the arch dissection.³⁹ Extensive release of the upper midface ligamentous structures has been advocated to facilitate upward rotation of the flap. Wide undermining of the orbicularis oculi muscle fibers may also assist in upward elevation. Cheek pad elevation in a superior-lateral vector can generally be achieved.²¹

There is a problem area in the subperiosteal dissection involving a transition from the temple to the zygoma. The easily accessible intermediate temporal fascial space and the easily accessible subperiosteal space of the midface must be connected to allow upward mobilization of the flap. The intermediate temporal fascia above the temporal fat pad must be incised to allow the transition onto the zygomatic periosteum. Undue traction on the frontal branch of the facial nerve can cause a temporary or permanent injury and hemiparesis. If the neck is to be rejuvenated, this approach can be combined with a periauricular incision.

Advantages of a purely subperiosteal upper face and midface lift with combined temporal and buccal sulcus incisions include ease of implementation, no necessity of infraorbital incision, and minimal risk of ectropion. The purely endoscopic upper face and midface lift technique is especially useful if modest elevation of the midface with no treatment of the orbicularis oculi muscle is necessary.

The lateral canthus may rotate upward in a pure subperiosteal dissection in the lateral brow and midfacial region. This can produce a “cat-like” appearance if pull is excessive or if the patient has preexisting superiorly positioned lateral canthus. In performing any surgery that elevates midfacial tissue in a superior-lateral direction, care must be taken that the interzygomatic (intermalar) distance does not become excessively wide. One must avoid increasing intermalar distance in any midfacial or temporal-midfacial procedure when the vector of pull of the malar fat pad is superior and lateral.

Combined Subperiosteal Techniques

There is a growing trend away from the purely subperiosteal face lift toward a combined approach—a

midfacial technique encompassing a subperiosteal dissection with a separate lateral brow technique. The frontal branch is thereby taken out of harm's way because no surgical dissection is necessary through the anatomically difficult temporal area. Rather, dissection is completely superior to the frontal branch of the facial nerve for the superior dissection (except for a small subgaleal or subperiosteal dissection in the lateral brow) and completely suborbicularis below the inferior orbital rim for the inferior dissection, well medial to where the frontal branch might be injured. This is the so-called safe zone approach to the midface, avoiding dissection in the lateral cheek.

Differentiation between the subperiosteal face lift and the endoscopic face lift–brow lift–midface lift is becoming blurred. Hybrid procedures combining minimal temporal incisions versus endoscopic incisions make the distinction between endoscopic and subperiosteal facial and brow rejuvenation procedures fluid.

The subperiosteal technique performed in a safe zone manner provides moderate rejuvenation of the upper face and midface. It is usually necessary to tighten the neck separately through a separate preauricular incision because neck rejuvenation is typically modest with this approach. It is therefore most widely used in younger patients.

Composite Face Lift Technique

This upper face–midface rejuvenation technique involves elevation of the entire face through conventional face lift incisions and a subciliary incision, with complete detachment of the pretarsal orbicularis oculi muscle and a suborbicularis plane of dissection. This technique results in a significant elevation of the lateral sideburn, often to a position above the ear. In addition, lateral canthal elevation may occur when the composite flap is elevated superiorly. This technique is important in that it introduced simultaneous midface and lower, upper, and lateral face elevation. Combining midfacial elevation with more conventional upper and lateral facial elevation will reduce the lateral sweep deformity.⁴⁰

Hamra⁴⁰ described repositioning of the orbicularis muscle to the orbital rim periosteum as a component of a composite rhytidectomy. This technique can be combined with a zygorbicular dissection and midface elevation.⁴¹ This operation involves separation of the pretarsal orbicularis muscle and inclusion in the flap, with subsequent dissection inferiorly and eventually below the zygomaticus muscle. This flap is then combined with a subcutaneous face lift dissection from below, above the level of the zygomaticus major muscles.

This technique combines several existing techniques with a composite, mask-like elevation of the face. Most

surgeons now have modified the suborbicularis dissection as it was originally described to retain a cuff of pretarsal orbicularis and to spare the anterior, temporal, and sideburn hairline.

Midface Lifts for Avoidance of Lateral Sweep Syndrome

The necessity of midfacial rejuvenation is growing. The lateral sweep appearance of the face is avoided by lifting the midface as well as the side and bottom of the face and neck. Camouflage techniques, such as a conventional lower blepharoplasty or arcus marginalis blepharoplasty, will not suffice to achieve midfacial rejuvenation in many patients with significant cheek ptosis (Fig. 47-24).

A harmoniously rejuvenated face should incorporate as many important youthful features with as few telltale signs and have no distortion of normal anatomy (Fig. 47-25). The lateral sweep phenomenon can predictably be precluded by concomitant midfacial and lateral-lower facial rejuvenation and avoidance of an excessive purely vertical vector at the level of the sideburn.

Postblepharoplasty Sequelae in Facial Rejuvenation

Avoidance of postblepharoplasty syndromes is imperative. Midfacial-lateral brow procedures have been modified to treat midfacial retraction caused by aggressive blepharoplasty. Classically, an accurate diagnosis is made between the three lamellae and their contribution to the lower eyelid problem. The degree of horizontal or vertical shortening or laxity is also determined to see how the reconstruction is to proceed. The most frequent postblepharoplasty problem is retraction of the anterior (skin and orbicularis muscle) and middle (orbital septum) lamellae. Surgeons have long recognized that correction of the lower eyelid deformity must simultaneously involve midface elevation. It is no longer acceptable to perform a traditional blepharoplasty and cause such deformities. The complication of ectropion or lateral orbital dystopia can be avoided or minimized by meticulous attention to not overresecting lower eyelid skin, not causing undue scarring in the orbital septum (middle lamella), and properly supporting the lower eyelid during any surgery (i.e., midfacial elevation, canthopexy, canthoplasty). Compared with suborbicularis dissection for midfacial elevation, midfacial procedures performed in a subperiosteal plane may be associated with a higher incidence of ectropion (Fig. 47-26).

It is also becoming common for surgeons to offer midfacial rejuvenation in their practices. It is difficult to rationalize not offering such techniques when a thorough knowledge of midfacial and lateral brow anatomy

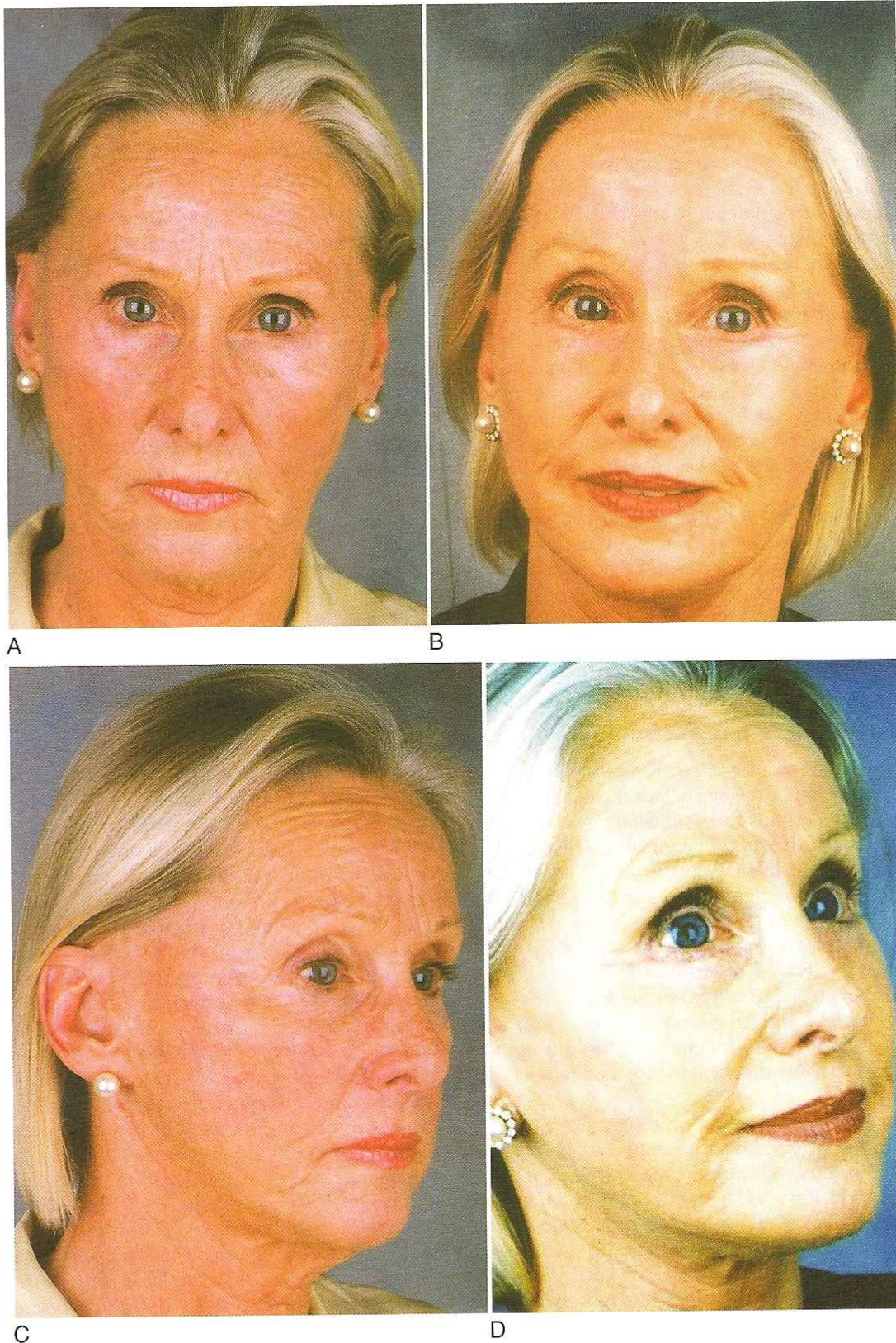

FIGURE 47-24. A and C, Preoperative views of a patient with previous face lift with no midface rejuvenation. B and D, Postoperative views after elevation of the midfacial tissues with reduction of the “lateral sweep” phenomenon.

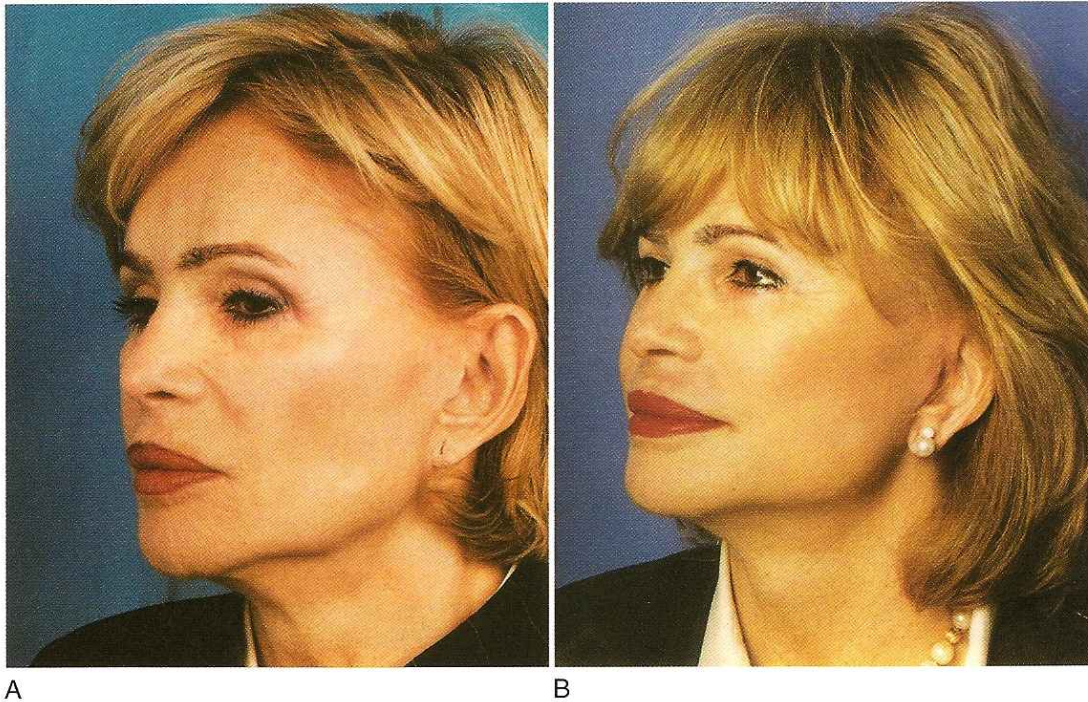


FIGURE 47-25. *A*, Preoperative view of a patient with previous face lift with midfacial sagging despite upper and lateral facial tightness. *B*, Postoperative view of the patient after a midfacial elevation (superficial cheek lift) along with a revisional face lift. (From Moelleken B: The superficial subciliary cheeklift, a technique for rejuvenating the infraorbital region and nasojugal groove: a clinical series of 71 patients. *Plast Reconstr Surg* 1999;104:1863.)

and a familiarity with various midfacial rejuvenation techniques can enhance our ability to rejuvenate the face more harmoniously. It is critical for surgeons performing complex lower blepharoplasties including revisions, forward set globes (negative vector orbital rim), and lower eyelid laxity to be familiar with mid-

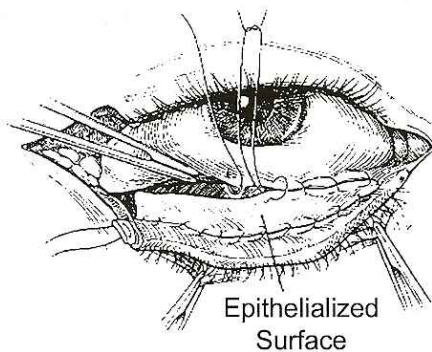



FIGURE 47-26. Palatal mucosal graft inserted into lower eyelid conjunctival surface to replace scarred or missing middle and posterior lamellar tissues. (From Shorr N: Madame butterfly procedure with hard palate graft: management of postblepharoplasty round eye and scleral show. *Facial Plast Surg* 1994;10:90.)

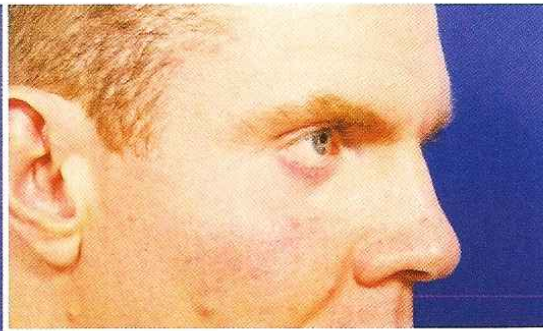facial rejuvenation techniques and ectropion repair and reconstruction before such procedures are undertaken. There is an increasing incidence of lower eyelid problems such as ectropion, lateral canthal dystopia, and excessive scleral show resulting from the widening use of midfacial procedures (Figs. 47-27 and 47-28).⁴² Schorr⁴³ described the Madame Butterfly procedure as an operation to treat ectropion and excessive scleral show after lower blepharoplasty. The dissection involves lysis of middle lamellar tethering cicatrix, complete canthotomy of the two limbs of the lateral canthus, lateral and inferomedial undermining of cheek tissue at the supraperiosteal level, and anchoring of suborbicularis oculi fat tissue to the periosteum of the orbital rim at the arcus marginalis.

LATERAL CANTHAL TIGHTENING PROCEDURES

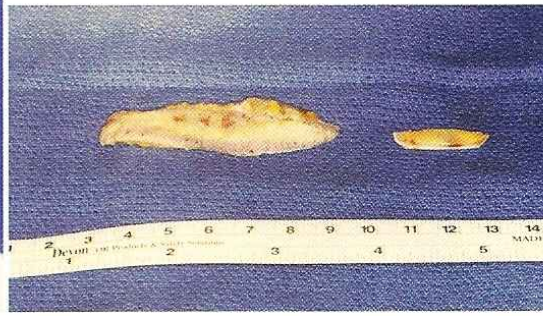One effective technique for mild postblepharoplasty syndrome is lateral canthal elevation with mild undermining of the orbicularis muscle, leaving a cuff of orbicularis muscle (Fig. 47-29). This technique uses an optional canthotomy and drill fixation of the suspension suture. More aggressive techniques may necessitate wider midfacial elevation. Another approach is



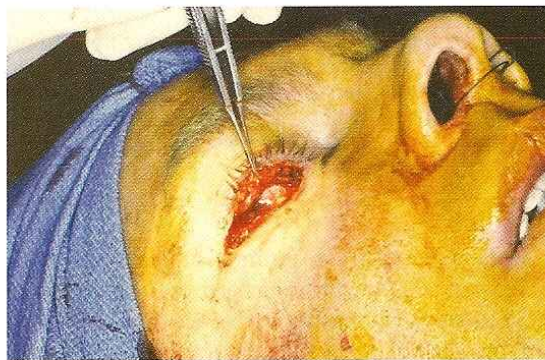A



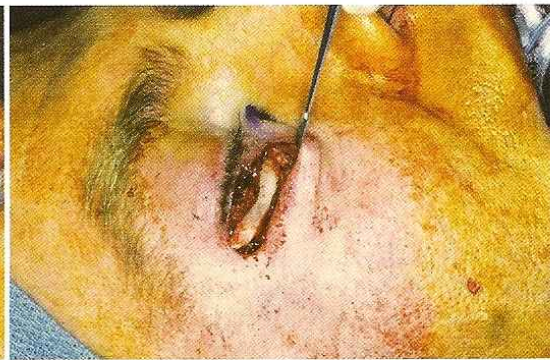
B




C



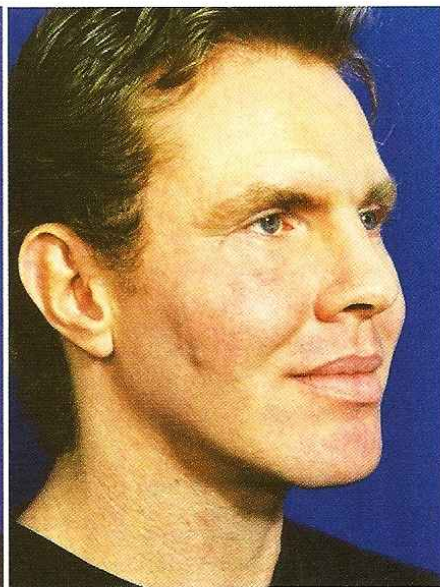
D



E



F



G

FIGURE 47-27. *A and B*, Preoperative ectropion and enophthalmos in a 32-year-old man. *C*, Grafts of LiveFill disarticulated fat-fascial grafts for autologous fill; chondromucosal graft for middle and posterior lamellar replacement. *D*, Intraoperative view of repair with partial inset of chondromucosal composite graft to replace posterior and middle lamellar scarring. Note extent of conjunctival and middle lamellar tissue actually missing after lysis of middle and posterior lamellar scarring. *E*, Intraoperative view of conjunctival surface of ectropion and enophthalmos repair. *F and G*, Postoperative view of repair of ectropion and enophthalmos with chondromucosal graft, superficial cheek lift, and lateral canthopexy.

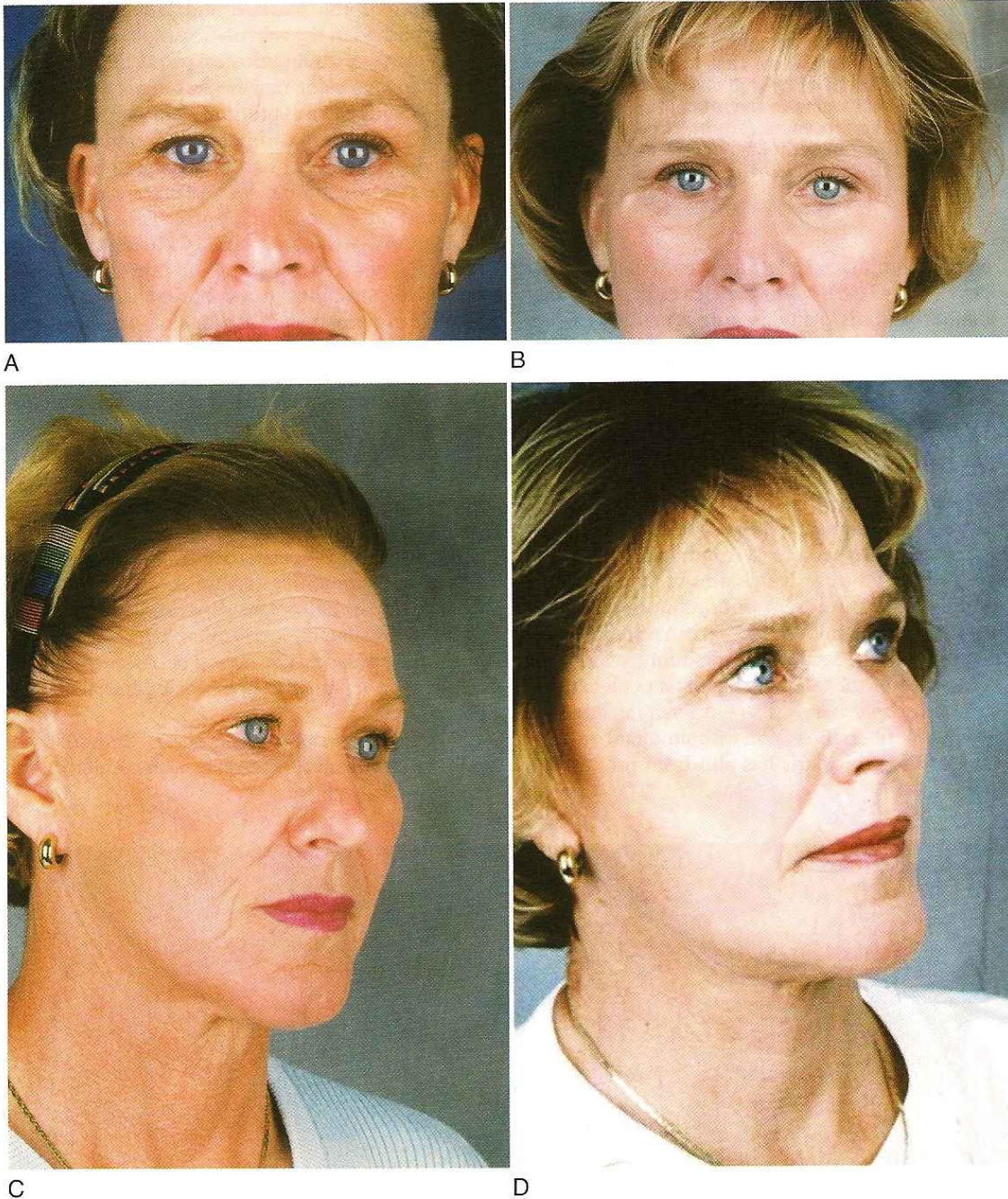

FIGURE 47-28. *A and C*, Preoperative views of a patient with postblepharoplasty hollowness. *B and D*, Postoperative views after midfacial rejuvenation and arcus marginalis release with transposition of fat into infraorbital hollow. In patients such as this, dermis-fat-fascia grafts are now inserted into the infraorbital and nasojugal hollows.

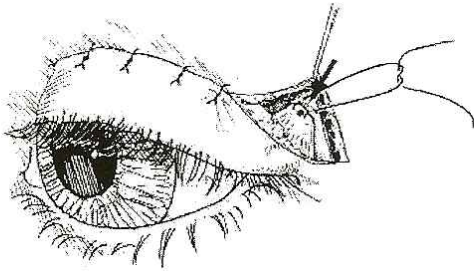


FIGURE 47-29. A technique for isolated lateral canthopexy for downward lateral cant to the lower lateral eyelid. A formal canthotomy with division of the canthal ligament and drill fixation to the orbital rim is generally performed with this procedure. (From McCord CD, Codner MA, Hester TR: Redraping the inferior orbicularis arc. *Plast Reconstr Surg* 1998;102:2471.)

to combine midfacial elevation with lateral canthopexy (Fig. 47-30). Midfacial elevation, preferably in a suborbicularis plane, is now a mainstay when canthopexy is performed. This allows the canthal reconstruction to heal without undue inferior retraction.

Crow's-Feet

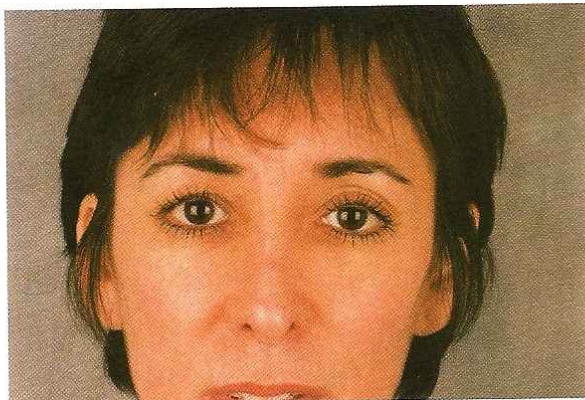Crow's-feet (lateral periorbicular wrinkles) are a stubborn problem with many suggested solutions. The etiology is muscle hyperactivity combined with senile degeneration of the overlying skin and the formation of rhytids. With the advent of botulinum toxin, the appearance of dynamic crow's-feet can be reduced on a temporary basis. Sectioning operations may result in recurrence of the lateral orbicularis oculi activity once microscopic nerve fibers regenerate into the healed muscle fibers. Elevation with simultaneous sectioning of the orbicularis has also been proposed.³⁴

Deep established rhytids may require laser resurfacing in addition to treatment of the underlying orbicularis muscle. Suborbicularis midfacial elevation predictably reduces crow's-feet deformity up to the level of the repair (see next section) (Fig. 47-31).

Midface Suborbicularis Technique

Elevation of the midface and lateral face can be accomplished in the subcutaneous plane, a suborbicularis plane, or a subperiosteal plane. Elevation at the subcutaneous plane may neglect many of the deeper signs of aging, such as ptotic orbicularis muscle, infra-orbital fat against the orbital septum, and ptotic malar fat pad. Advantages of accessing the upper face and midface in a suborbicularis plane are ease of performance, ability to tailor the orbicularis oculi muscle, avoidance of swelling associated with subperiosteal dissection, faster recovery time, and prevention of post-operative ectropion. In a suborbicularis plane, it is possible to perform simultaneous lower blepharoplasty with treatment of fat herniation and orbicularis descent. The inherent advantages of a suborbicularis technique are the ability to correct a ptotic orbicularis muscle and the ability to move tissues otherwise tethered by an unyielding periosteum. This technique is especially suited when lower eyelid rejuvenation or microadjustment is necessary. Risk to the frontal branch of the facial nerve is remote. If a 4- to 5-mm cuff of pretarsal orbicularis oculi muscle is maintained, orbicularis hypotonicity is rare. As a cautionary note, the patient should not have botulinum toxin injections in the lateral periorbital region during the immediate preoperative period because hypotonicity can be manifested after upper or midfacial elevation procedures.

The zygorbicular plane of midfacial elevation is basically a suborbicularis approach to the midface. It also



A



B

FIGURE 47-30. A, Preoperative view of a patient with downward cant of the lateral canthus. B, Postoperative view after selective elevation of the lateral canthus plus midfacial elevation.

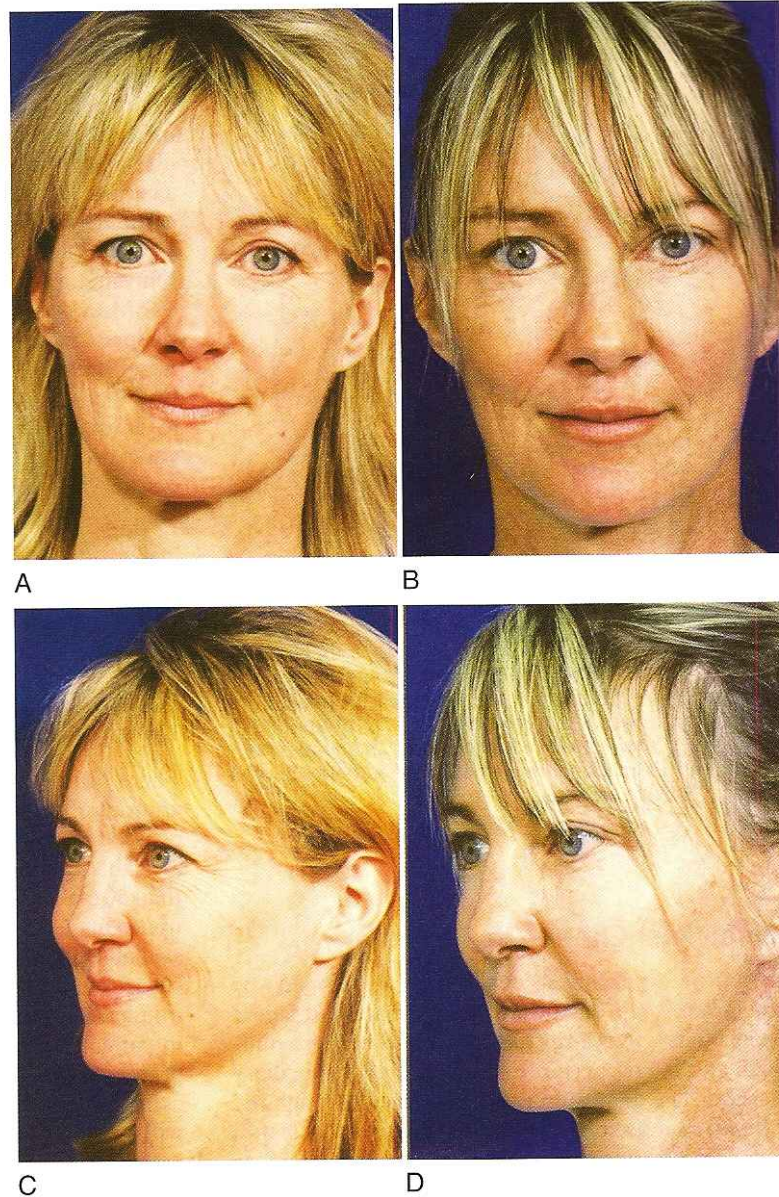


FIGURE 47-31. *A* and *C*, Preoperative views of a 45-year-old woman with crow's-feet and midfacial descent. *B* and *D*, Postoperative views after superficial (suborbicularis) cheek lift with orbicularis muscle tailoring.

uses a second plane, underneath the medial portions of the zygomaticus major and minor. This technique is combined with a composite face lift, in which a composite face lift flap is developed and rotated upward. However, a component of the composite lift may be an extreme elevation of the sideburn. Implications of this sideburn loss should be discussed preoperatively with the patient, and this technique may not be appropriate for patients with an already high sideburn. In development of the composite flap, the pretarsal orbicularis oculi muscle is taken from its lower eyelid attachments with no cuff remaining on the lower

eyelid.⁴¹ When no cuff of pretarsal orbicularis muscle is left behind to support the lower eyelid, there is elevated potential for dystonia of the lower lid, ectropion, or lid retraction. Dissection at the suborbicularis level has inherently less swelling than when the subperiosteal space is entered.

Many hybrid techniques are emerging that combine aspects of isolated techniques (Fig. 47-32). In one such technique, a subperiosteal dissection is combined with a lateral temporal incision. The malar fat pad is elevated superolaterally and fixated to the deep temporal fascia.

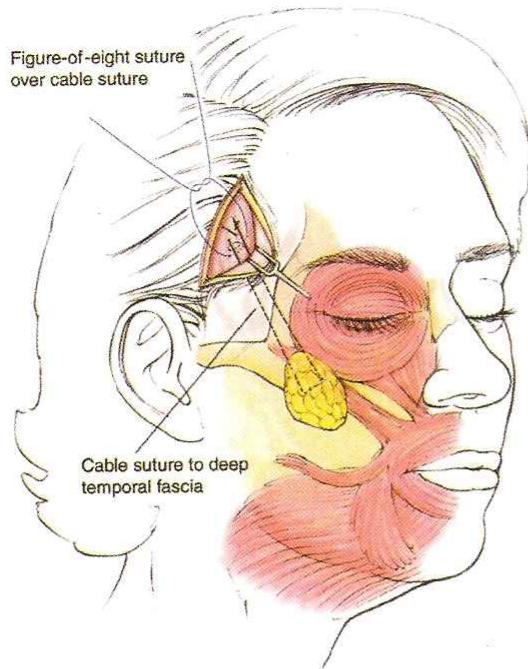


FIGURE 47-32. A technique for midfacial complex elevation with direct sutures from the malar fat pad to the deep temporal fascia in combination with a subperiosteal dissection. (From Paul MD: Morphologic and gender considerations in midface rejuvenation. *Aesthetic Surg J* 2001;21:349.)

Superficial Cheek Lift Technique

With the superficial cheek lift developed by Moelleken,⁴⁴ rejuvenation of the midface and lateral periorbital region can effectively be achieved by a midfacial and lateral periorbital lift through a subciliary incision. The dissection is carried down through the orbicularis muscle, with preservation of a 4- to 5-mm cuff of pretarsal orbicularis muscle (Figs. 47-33 to 47-36). A suborbicularis dissection is then undertaken to free the malar fat pad and midface from its midfacial attachments. The entire midfacial complex is advanced superiorly, and the cuff of cheek orbicularis is anchored to the so-called intermediate temporal fascia. This has resulted in predictable rejuvenation of the midfacial and lateral periorbital region. The extended healing time of the subperiosteal approach is avoided. The morbidity of a canthotomy is also avoided. Microadjustment of the orbicularis oculi muscle is possible before closure of the subciliary incision. The superficial cheek lift does require familiarity with the midface and lower eyelid and may be technically more difficult than midfacial techniques not performed through a subciliary incision; its reward has been a negligible incidence of ectropion. Complications have been minor and include palpable

fixation sutures, subtle facet formation at the lateral inferior periorbital region, postoperative lateral periorbital incisional swelling, and visible scars requiring minor scar revisions. Use of short lateral periorbital incisions, careful adjustment of tension on the cheek lift flap, and taping of the lateral periorbital area for a period of 3 days postoperatively can minimize these complications.

In keeping with the trend for more comprehensive rejuvenation, autologous disarticulated dermis-fat or SMAS grafts can be placed in regions of excessive hollowness at the same time as the midfacial elevation is performed (Fig. 47-37). With the modern realization that panfacial fat atrophy is a heavy contributor to midfacial aging, facial fat grafting is gaining wide acceptance. The survival of nontraumatized dermis-fat-fascia grafts is superior to that of injected fat.

This operation provides predictable elevation of midfacial tissues with effacement of the infraorbital hollow region in a technically straightforward plane of dissection (Fig. 47-38).

Limitations in Midfacial Tissue Elevation

There has been a disturbing trend to maximize the amount of midfacial tissue elevated during midfacial or upper facial-midfacial procedures. The amount of available tissue for elevation is limited. There is less than 50 cm² of tissue total from the lower eyelid to the upper lip. Only approximately 1 to 4 cm² of tissue is available for resection and elevation. More tissue can be resected when solid canthal reconstruction with midfacial tissue support can be established, and only in patients with very lax cheek skin. In patients with previous blepharoplasty, there is typically no tissue that can be resected. Rather, all elevated midfacial tissues will be required to allow middle lamellar scarring, downward pull due to incisional tightening, and lateral canthal reconstruction. Surgeons experienced with the midface do not attempt aggressive midfacial lifts.

Excessive elevation of midfacial tissues can result in ectropion, round eye deformity, and orbital exposure with keratopathy. In patients who have had aggressive midfacial elevation procedures, an early sign of tightness in the midface is a downward lower eyelid pull when the patient opens the mouth and forces the upper lip over the front teeth.

Subperiosteal Subciliary Procedures

Many subperiosteal subciliary techniques are described with canthotomy and a subperiosteal dissection. Complications can be significant and include prolonged swelling associated with the subperiosteal dissection

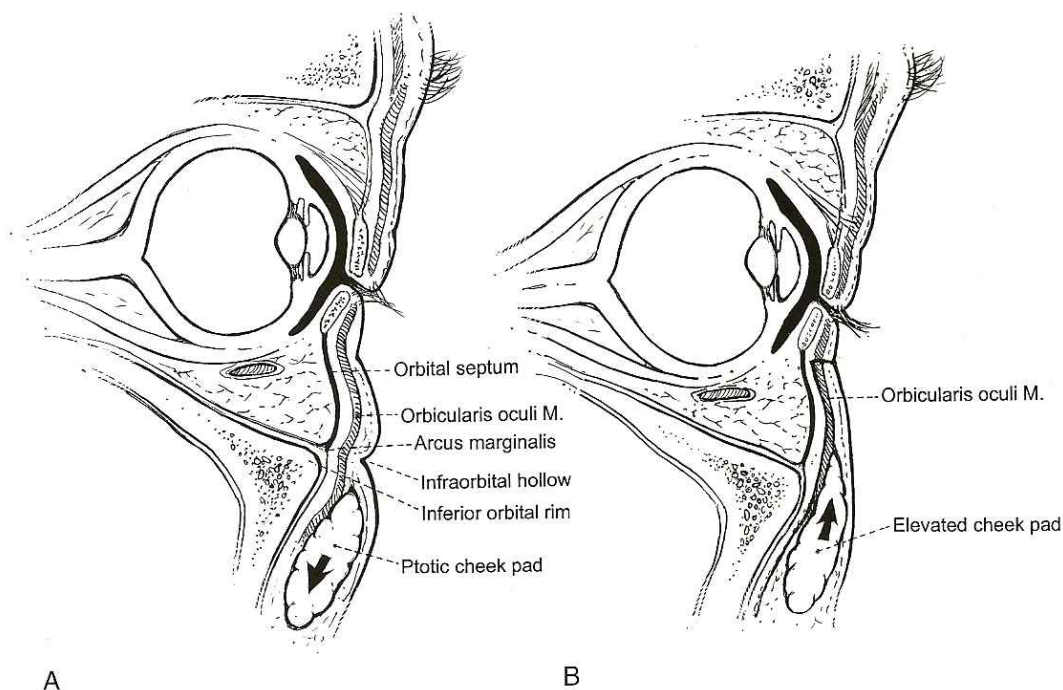
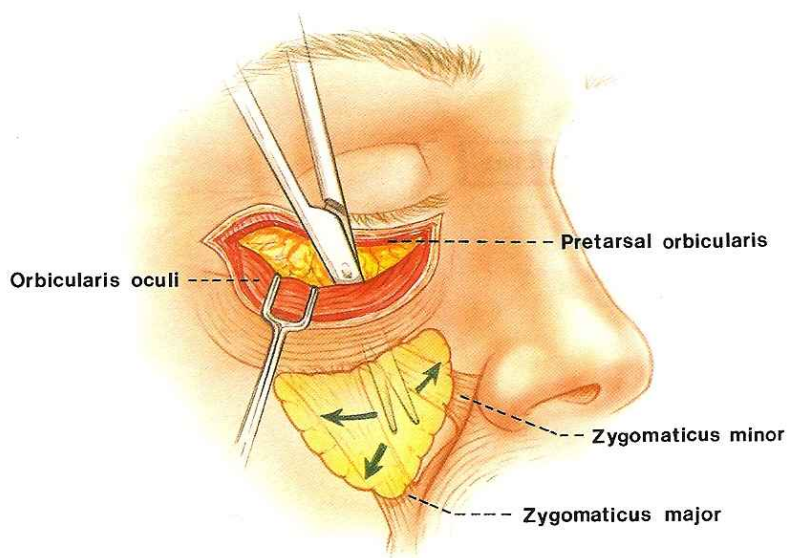


FIGURE 47-33. *A* and *B*, Lateral view of the upper cheek anatomy. Note role of orbicularis oculi muscle (distal fibers) with malar fat pad. The suborbicularis oculi fat layer, located deep to the orbicularis oculi muscle, is simply a gliding layer for the orbicularis muscle to function properly. The suborbicularis oculi fat is by itself not a structural layer capable of elevating and fixating the midfacial tissues. (From Moelleken B: The superficial subiliary cheek lift, a technique for rejuvenating the infraorbital region and nasojugal groove: a clinical series of 71 patients. *Plast Reconstr Surg* 1999;104:1863.)

FIGURE 47-34. Superficial cheek lift dissection with suborbicularis dissection; a pretarsal orbicularis cuff is preserved, and lateral suborbicular dissection is avoided. These two cautionary steps will prevent temporary or permanent denervation of the orbicularis with postoperative ectropion. (From Moelleken B: The superficial subiliary cheek lift, a technique for rejuvenating the infraorbital region and nasojugal groove: a clinical series of 71 patients. *Plast Reconstr Surg* 1999;104:1863.)



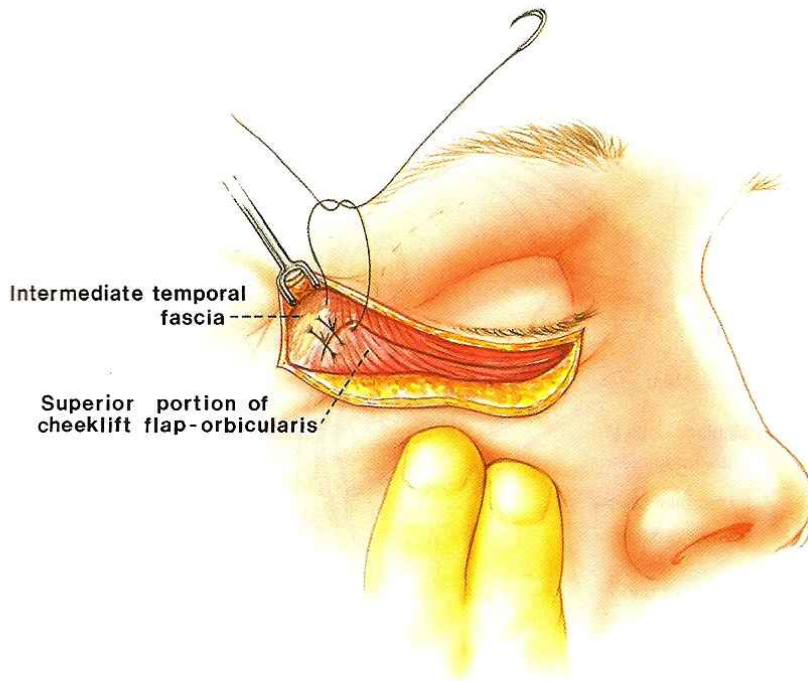


FIGURE 47-35. Securing of the elevated midfacial cheek pad complex to the intermediate temporal fascia by the orbicularis muscle and its attachments to the malar fat pad. (From Moelleken B: The superficial subciliary cheeklift, a technique for rejuvenating the infraorbital region and nasojugal groove: a clinical series of 71 patients. *Plast Reconstr Surg* 1999;104:1863.)

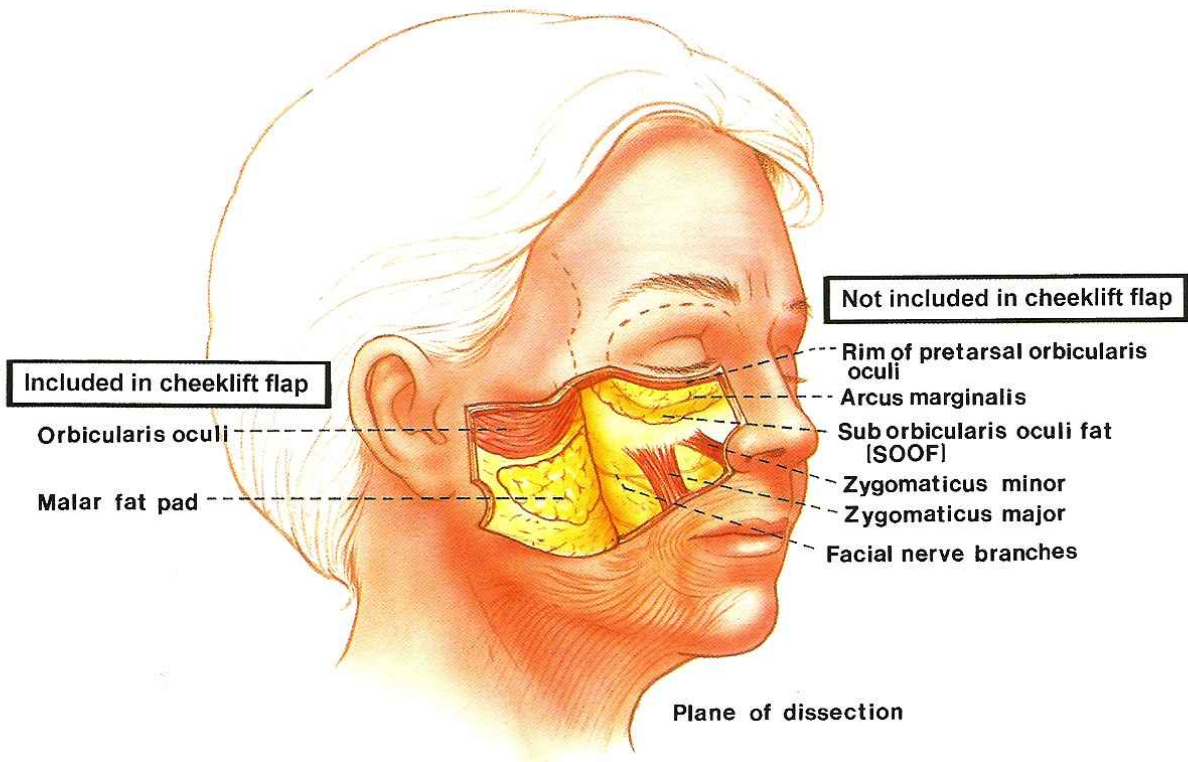
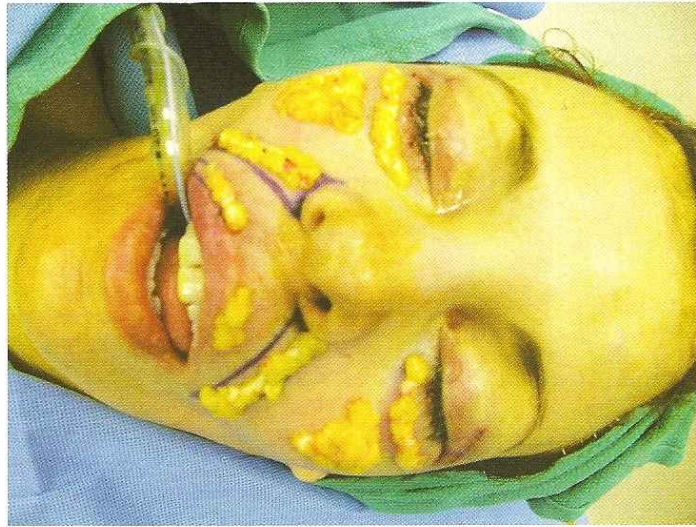
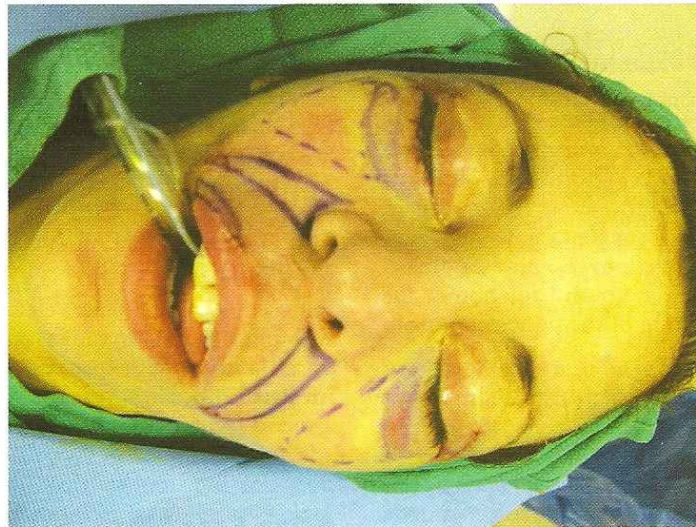
FIGURE 47-36. Anatomic cutaway of the superficial cheek lift operation to demonstrate level of dissection. The level of dissection of the superficial cheek lift is suborbicularis, leaving the zygomaticus muscles behind. (From Moelleken B: The superficial subciliary cheeklift, a technique for rejuvenating the infraorbital region and nasojugal groove: a clinical series of 71 patients. *Plast Reconstr Surg* 1999;104:1863.)



A



B

FIGURE 47-37. A, Disarticulated dermis-fat-fascia grafts before placement in infraorbital hollows, malar fat pads, nasolabial folds, and lips. B, A superficial cheek lift, face and neck lift, and lateral canthopexy were performed immediately after placement of the disarticulated autologous dermis-fat-fascia grafts. Large soft tissue augmentation procedures are now becoming commonplace.

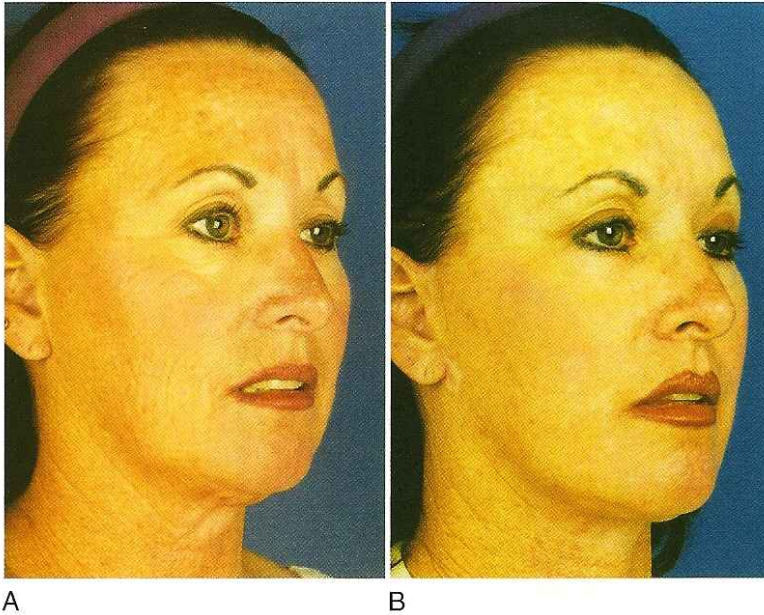


FIGURE 47-38. *A*, Preoperative view of a woman with infraorbital hollowness and cheek pad complex ptosis. *B*, Postoperative view after a superficial cheek lift in combination with a face and neck lift, resulting in rejuvenation of the upper, mid, and lower face.

and lateral canthal distortion associated with a canthotomy. This technique and all midfacial techniques require considerable experience with the midface and lower eyelid. Advocates of this technique have abandoned the canthotomy.⁴⁵

The subperiosteal cheek lift, despite its difficulty and potential complications, can produce excellent midface elevation when it is performed by surgeons with expertise in midfacial procedures. It is important to avoid a long lateral periorbital incision and whenever possible to avoid a canthotomy. Because the periosteum is an unyielding layer, upward rotation of the flap may necessitate scoring of the periosteum from below during flap elevation.

TRANSMALAR SUBPERIOSTEAL MIDFACE LIFT

The transmalar subperiosteal midface lift is a subperiosteal technique that anchors the zygomaticus muscle origins to the deep temporal fascia; it is accomplished with a blind dissection through the skin on the zygoma with minimal skin and SMAS undermining.⁴⁶ A theoretical disadvantage of this technique may be the concentration of the entire vector of the lift in a single suture. Temple and gingival sulcus incisions are the most common for these types of procedures.⁴⁷

Endoscopic Midface Techniques

Endoscopic techniques performed at a subperiosteal level excel at rejuvenating the upper and middle face.

They share mobilization of the midface at a subperiosteal level, careful dissection over the zygoma where the frontal branch of the facial nerve runs, and anchoring of the elevated flap to higher tissues, usually the deep temporal fascia. These techniques are frequently combined with separate incisions for a neck lift or upper or lower blepharoplasty.⁴⁸

ENDOSCOPIC MALAR AND MIDFACE SUSPENSION

Endoscopic subperiosteal elevation is accomplished with anchoring of the midfacial tissues to the deep temporal fascia with suspension sutures.⁴⁹ It does not involve a subciliary incision, so concomitant blepharoplasty will require a separate incision.

Asian Face Lifts

Many Asian patients possess distinct facial contours, typically a brachycephalic skull with a prominent zygoma and mandibular angle. A subperiosteal procedure with upper buccovestibular and subciliary incisions has been used to rejuvenate the temporal and midfacial region of the Asian face in a natural manner, especially in combination with a multivector face lift.⁵⁰ Special care must be taken not to increase intermalar distance by upward and lateral vector lifts of the cheek pad complex during midfacial or temple-midfacial procedures.

Skeletal Augmentation to Achieve Rejuvenation (Cheek or Composite Implants)

Augmentation of underlying bony structures in the supraorbital-temporal ridge area and malar-midface areas may counteract the effects of aging by filling in tissues lost to senile subcutaneous atrophy.⁵¹⁻⁵³ The placement of cheek implants or submalar implants may successfully replace soft tissue loss due to subcutaneous tissue atrophy. Careful analysis of the facial zones and tissue deficits is essential. There is a tendency away from the older style “button implants” placed on top of the lateral zygoma; these are often visible and unattractive. Increased intermalar distance, the “praying mantis effect,” should be avoided in placement of any midfacial implants.

When profound midfacial wasting is present (as in patients with human immunodeficiency virus infection who are taking multiple antiviral medications), large piriform aperture-midfacial implants can be fashioned on the basis of a computed tomographic scan-generated moulage. The implants are then customized preoperatively, and minor revisions are performed in the operating room. In general, an upper buccal sulcus incision is sufficient to place even large custom implants in the midface and piriform area. This technique is most applicable for patients who have taken antivirals for human immunodeficiency virus infection and have profound facial wasting. Now that 20+-year survival from human immunodeficiency virus infection is commonplace, extensive soft tissue augmentation is becoming a technical challenge.

Fat Injection and Grafting

There is an increasing trend toward subcutaneous fat injection under rhytidectomy flaps before closure to combat the facial fat atrophy in the subcutaneous layers.⁵⁴ Repeated injections may be necessary because of the inherently low survival of fat subjected to the trauma of liposuction, purification, and injection (20% to 25% in most series at best). Nevertheless, injection of fat may provide a means of augmenting a large tissue plane and combating facial fat atrophy. Autologous grafts of dermis-fat survive more predictably than do aspirated fat grafts (Fig. 47-39).

Practitioners who have considerable experience with fat injection stress the necessity of handling the fat gently and harvesting and transferring small allotments of fat. A blunt cannula may minimize trauma to the fat cells. The limiting factor in fat injection is the survival of the grafted tissue. Survival reports vary, but it seems that most fat transplantation has minimal

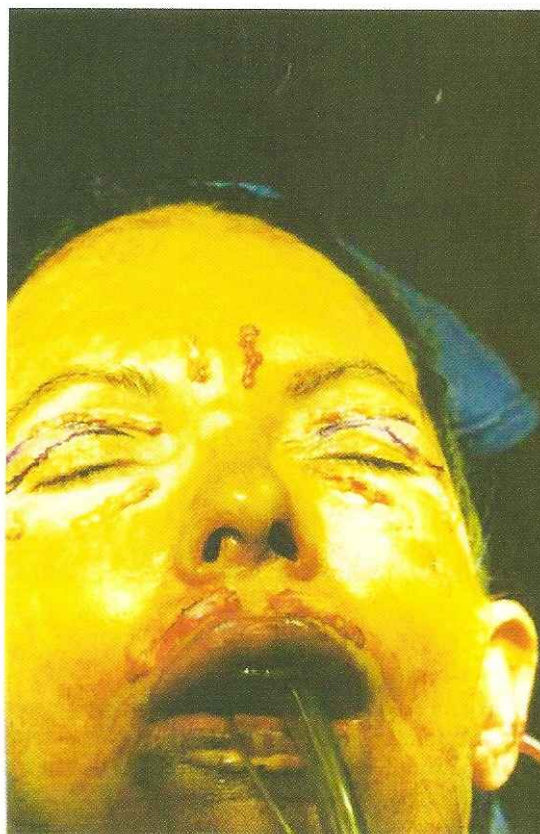

FIGURE 47-39. Rhytidectomy patient before placement of harvested SMAS grafts into critical areas: supraorbital sunkenness from previous blepharoplasty, infraorbital groove hollowness (in combination with a superficial cheek lift), upper and lower lip for augmentation, and glabellar furrow grafts; carefully harvested fat is also injected underneath face lift rhytidectomy flaps and into hollow created by atrophy of temporal fat pad.

permanent survival; one study reported a 3% to 4% 14-month survival after the last transplantation session,⁵⁵ whereas others report successful long-term survival in grafted patients, even with Romberg syndrome.⁵⁶ There may be some utility to deep-frozen autologous fat as a filler.⁵⁷ One emerging theme is that if fat is used as a significant volume filler, repeated injections are necessary over time, and the longevity of the grafts is yet undetermined.

Care must be taken not to inject fat into areas covered by excessively thin flaps because the fat may then be visible as a subcutaneous irregularity. This presents a particular problem because fat that does survive injection tends to be fibrous and firm. One area that seems unsuited for routine fat injection is the infraorbital hollow region in patients with thin skin (Fig. 47-40). On occasion, injected fat can form calcific nodules, which require direct excision. In some

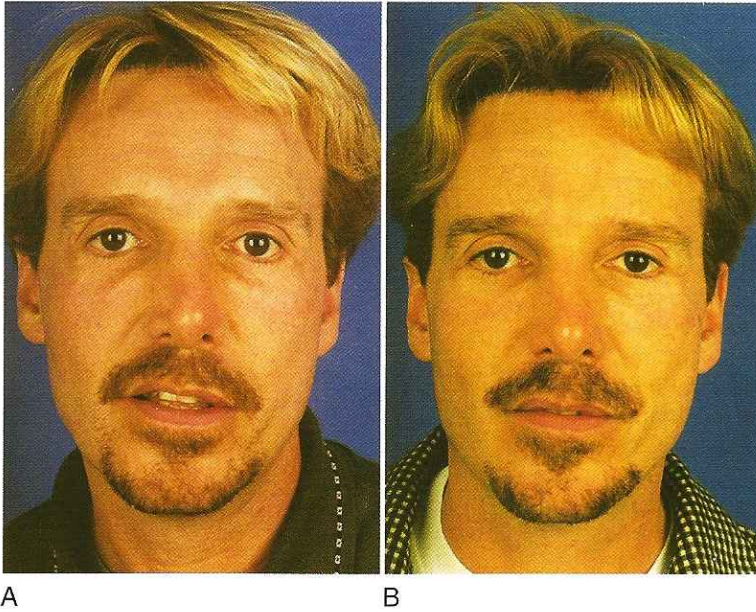


FIGURE 47-40. *A*, Preoperative view of a patient who had previously undergone subcutaneous injection of fat, which survived as a lumpy subcutaneous growth. Attempts at removal of the fat with liposuction and direct excision had failed, and the patient suffered from dry eye syndrome and lateral canthal dystopia. *B*, Postoperative view after removal of fat, canthal reconstruction, and superficial cheek lift.

circumstances, direct placement of SMAS or dermis-fat-fascia grafts into glabellar furrows, nasolabial folds, and infraorbital hollow regions may be preferable to fat injection.

CONCLUSION


There is a trend toward customization of aesthetic procedures based on anatomy and surgical findings. Plastic surgeons should endeavor to correct more signs of aging with fewer stigmata of surgery and more minimal incisions. Advances in understanding of midfacial and temporal anatomy have introduced surgeons to the idea of customizing rejuvenation surgery to needs of the individual patient.

REFERENCES

- Matarasso A, Hutchinson OH: Evaluating rejuvenation of the forehead and brow: an algorithm for selecting the appropriate technique. *Plast Reconstr Surg* 2000;106:687.
- Stuzin J, Wagstrom L, Kawamoto H, Wolfe S: Anatomy of the frontal branch of the facial nerve: the significance of the temporal fat pad. *Plast Reconstr Surg* 1989;83:265.
- Abul-Hassan H, Von Drasel Ascher G, Acland R: Surgical anatomy and blood supply of the fascial layers of the temporal region. *Plast Reconstr Surg* 1986;77:17.
- Hing DN, Buncke H, Alpert BS: Use of the temporoparietal-free fascial flap in the upper extremity. *Plast Reconstr Surg* 1988;81:534.
- Ramirez OM, Maillard GE, Musolas A: The extended subperiosteal facelift: a definitive soft tissue remodeling for facial rejuvenation. *Plast Reconstr Surg* 1991;88:141.
- Campiglio GL, Candiani P: Anatomical study on the temporal fascial layers and their relationships with the facial nerve. *Aesthetic Plast Surg* 1997;21:72.
- Mendelson BC, Muzaffar AR, Adams WP: Surgical anatomy of the midcheek and malar mounds. *Plast Reconstr Surg* 2002;110:885, discussion 897.
- Knize DM: An anatomically based study of the mechanism of eyebrow ptosis. *Plast Reconstr Surg* 1996;97:1321.
- Yaremchuk MJ: Subperiosteal and full-thickness skin rhytidectomy. *Plast Reconstr Surg* 2001;107:1585.
- Freund RM, Nolan WB 3rd: Correlation between brow lift outcomes and aesthetic ideals for eyebrow height and shape in females. *Plast Reconstr Surg* 1996;97:1343.
- Nordstrom RE, Greco M, Vitagliano T: Correction of sideburn defects after facelift operations. *Aesthetic Plast Surg* 2000;24:429.
- Brennan HG, Toft KM, Dunham BP, et al: Prevention and correction of temporal hair loss in rhytidectomy. *Plast Reconstr Surg* 1999;104:2219, discussion 2226.
- Camirand A, Doucet J: A comparison between parallel hairline incisions and perpendicular incisions when performing a face lift. *Plast Reconstr Surg* 1997;99:10. Comment in *Plast Reconstr Surg* 1998;101:1743.
- Troilius C: A comparison between subgaleal and subperiosteal brow lifts. *Plast Reconstr Surg* 1999;104:1079.
- Fleming RW, Mayer TG: Open versus closed brow lifting. *Facial Plast Surg* 2000;8:361.
- Dayan SH, Perkins SW, Vartanian AJ, Wiesman IM: The forehead lift: endoscopic versus coronal approaches. *Aesthetic Plast Surg* 2001;25:35.
- Ramirez OM: Transblepharoplasty forehead lift and upper face rejuvenation. *Ann Plast Surg* 1996;37:577.
- Sullivan MJ: Male brow surgery. *Facial Plast Surg* 1999;7:421.
- Moody FP, Losken A, Bostwick J 3rd, et al: Endoscopic frontal branch neurectomy, corrugator myectomy, and brow lift for forehead asymmetry after facial nerve palsy. *Plast Reconstr Surg* 2001;108:218.
- Dyer WK 2nd, Yung RT: Botulinum toxin-assisted brow lift. *Facial Plast Surg* 2000;8:343.
- Namazie AR, Keller GS: Current practices in endoscopic brow and temporal lifting. *Facial Plast Surg Clin North Am* 2001;9:439.
- Nassif PS, Koskoska MS, Homan S, et al: Comparison of subperiosteal vs subgaleal elevation techniques used in forehead lifts. *Arch Otolaryngol Head Neck Surg* 1998;124:1209.
- Byrd HS: The extended browlift. *Clin Plast Surg* 1997;24:233.

24. Miller TA, Rudkin G, Honig M, et al: Lateral subcutaneous brow lift and interbrow muscle resection: clinical experience and anatomic studies. *Plast Reconstr Surg* 2000;105:1120.
25. Kikkawa DO, Miller SR, Batra MK, Lee AC: Small incision nonendoscopic browlift. *Ophthalmic Plast Reconstr Surg* 2000;16:28.
26. Holcomb JD, McCullough EG: Trichophytic incisional approaches to upper facial rejuvenation. *Arch Facial Plast Surg* 2001;3:48.
27. Ahn MS, Catten M, Maas CS: Temporal brow lift using botulinum toxin A. *Plast Reconstr Surg* 2000;105:1129.
28. Roberts TL 3rd, Ellis LB: In pursuit of optimal rejuvenation of the forehead: endoscopic brow lift with simultaneous carbon dioxide laser resurfacing. *Plast Reconstr Surg* 1998;101:1075.
29. Ramirez OM, Pozner JN: Laser resurfacing as an adjunct to endo-forehead lift, endofacelift, and biplanar facelift. *Ann Plast Surg* 1997;38:315, discussion 321.
30. Ramirez OM, Pozner JN: Subperiosteal minimally invasive laser endoscopic rhytidectomy: the SMILE facelift. *Aesthetic Plast Surg* 1996;20:463.
31. Owsley JQ: Lifting the malar fat pad. *Plast Reconstr Surg* 1993;91:463.
32. Nicoletis C, Sitbon E, Cadot B, Marsot-Dupuch K: The middle third of the face in facial lift: lipopexy of the premalar fatty pad [in French]. *Ann Chir Plast Esthet* 1992;37:76.
33. McCord CD, Codner MA, Hester TR: Redraping the inferior orbicularis arc. *Plast Reconstr Surg* 1998;102:2471.
34. Fogli AL: Orbicularis muscleplasty and facelift: a better orbital contour. *Plast Reconstr Surg* 1995;96:1560.
35. Hinderer UT, Urriolagoita F, Vildosola R: The blepharopriorbitoplasty: anatomical basis. *Ann Plast Surg* 1987;18:437.
36. Trepsat F: Facelift of the malar, jugal and nasolabial regions. *Ann Chir Plast Esthet* 1994;39:597.
37. Longaker MT, Glat PM, Zide B: Deep-plane cervicofacial "hike": anatomic basis with dog-ear blepharoplasty. *Plast Reconstr Surg* 1997;99:16.
38. Kroll SS, Reece GP, Robb G, Black J: Deep-plane cervicofacial rotation-advancement flap for reconstruction of large cheek defects. *Plast Reconstr Surg* 1994;94:88.
39. Heinrichs HL, Kaidi AA: Subperiosteal face lift: a 200-case, 4-year review. *Plast Reconstr Surg* 1998;102:843.
40. Hamra ST: Composite rhytidectomy. *Plast Reconstr Surg* 1992;90:1.
41. Hamra ST: The zygorbicular dissection in composite rhytidectomy: an ideal midface plane. *Plast Reconstr Surg* 1998;102:1646.
42. Edelstein C, Balch K, Schorr N, Goldberg RA: The transeyelid subperiosteal midface-lift in the unhappy postblepharoplasty patient. *Semin Ophthalmol* 1998;13:107.
43. Shorr N: Madame Butterfly procedure with hard palate graft: management of postblepharoplasty round eye and scleral show. *Facial Plast Surg* 1994;10:90.
44. Moelleken B: The superficial subciliary cheeklift, a technique for rejuvenating the infraorbital region and nasojugal groove: a clinical series of 71 patients. *Plast Reconstr Surg* 1999;104:1863.
45. Gunter JP, Hackney FL: A simplified transblepharoplasty subperiosteal cheek lift. *Plast Reconstr Surg* 1999;103:2029.
46. Finger ER: A 5-year study of the transmalar subperiosteal midface lift with minimal skin and superficial musculoaponeurotic system dissection: a durable, natural appearing lift with less surgery and recovery time. *Plast Reconstr Surg* 2001;107:1273.
47. Hobar PC, Flood J: Subperiosteal rejuvenation of the midface and periorbital area: a simplified approach. *Plast Reconstr Surg* 1999;104:842.
48. DelaFuente A, Sanatamaria AB: Facial rejuvenation: a combined conventional and endoscopic assisted lift. *Aesthetic Plast Surg* 1996;20:471.
49. Anderson RD, Lo MW: Endoscopic malar/midface suspension procedure. *Plast Reconstr Surg* 1998;102:2196.
50. Lee Y, Hong JJ: Multiplane face lift with the subperiosteal dissection for Orientals. *Plast Reconstr Surg* 1999;104:237.
51. Whitaker LA, Bartlett SP: Skeletal alterations as a basis for facial rejuvenation. *Clin Plast Surg* 1991;18:197.
52. Binder WJ: Submalar augmentation: a procedure to enhance rhytidectomy. *Ann Plast Surg* 1990;24:200.
53. Binder WJ, Moelleken BRW, Tobias G: Aesthetic facial implants. In Papel ID, ed: *Facial Plastic and Reconstructive Surgery*, 2nd ed. New York, Thieme, 2002:276-298.
54. Coleman SR: Structural fat grafts: the ideal filler? *Clin Plast Surg* 2001;28:111.
55. Eremia S, Newman N: Long-term follow-up after autologous fat grafting: analysis of results from 116 patients followed at least 12 months after receiving the last of a minimum of two treatments. *Dermatol Surg* 2000;26:1150.
56. Guerrerosantos J: Long-term outcome of autologous fat transplantation in aesthetic facial recontouring: sixteen years of experience with 1936 cases. *Clin Plast Surg* 2000;27:515.
57. Bertossi D, Kharouf S, d'Agostino A, et al: Facial localized cosmetic filling by multiple injections of fat stored at -30 degrees C. Techniques, clinical follow-up of 99 patients and histological examination of 10 patients [in French]. *Ann Chir Plast Esthet* 2000;45:548, discussion 555.

PN 9996038270



9 789996 038273