

# The Superficial Subciliary Cheek Lift, A Technique for Rejuvenating the Infraorbital Region and Nasojugal Groove: A Clinical Series of 71 Patients

**Brent Moelleken, M.D.**

*Beverly Hills, Calif.*

The superficial subciliary cheek lift is an aesthetic operation to rejuvenate the infraorbital region and midface. It smoothes and rejuvenates the nasojugal groove, the nasolabial fold, and cheekpad with a direct pull upward. This technique is a technically straightforward procedure that does not involve dissection at a subperiosteal level, endoscopic equipment, a formal canthotomy, or drill fixation. It does not produce superior displacement of the lateral canthus. The entire operation is performed through an extended subciliary incision. Fixation is accomplished to the intermediate temporal fascia just lateral to the lateral orbital rim. No reliance is placed on the lower eyelid for tightening the midface region. The superficial subciliary cheek lift can be performed as a separate operation or in conjunction with a face lift. It is an aesthetic procedure that is an adjunct to a subciliary lower blepharoplasty when rejuvenation of the upper midface and nasojugal area is also required. A series of 71 patients is presented, with excellent 6-month to 3-year results and an acceptably low complication rate. (*Plast. Reconstr. Surg.* 104: 1863, 1999.)

With age, a hollow infraorbital appearance occurs. The infraorbital rim and infraorbital fat pockets become exposed and accentuated. Malar pad ptosis and a prominent nasojugal groove accentuate these aging features. These problems are due, in large part, to the downward drift of the cheekpad complex, which consists of the orbicularis muscle, the thick malar fat pad, the suborbicularis oculi fat, and the associated subcutaneous tissues.

The superficial subciliary cheek lift raises, as

a unit, all these elements of the infraorbital region and upper midface and repositions them higher.<sup>1,2</sup> This composite unit then covers the infraorbital rim with a thick cheekpad tissue flap, rendering it smoother and more youthful looking. The infraorbital rim is now covered with the thick skin and subcutaneous tissue of the malar fat pad rather than the atrophic infraorbital skin. Elevation of the cheekpad also directly reduces the bulk of the upper nasolabial fold. A subcutaneous and suborbicularis dissection avoids the necessity of subperiosteal dissection or crosscuts in the unyielding periosteum; rather, a superficial dissection allows a very pliable cheekpad to rotate upward freely. Anchoring this flap to the intermediate temporal fascia above the level of the canthus allows a more superior purchase on the cheek lift flap than the inferior orbital rim.

### ANATOMY

The anterior lamella consists of the skin and orbicularis muscle. The middle lamella consists of the orbital septum, which originates from the arcus marginalis and inserts into the inferior tarsal margin. The posterior lamella includes the conjunctiva and lower eyelid retractors. The suborbital orbicularis oculi tissue is the continuum of suborbital fat with the malar fat pad.

Received for publication March 26, 1999; revised May 12, 1999.

Presented at the Annual Meeting of the California Society of Plastic Surgeons, Santa Barbara, California, March 14, 1998, and at the Annual Meeting of the American Society for Aesthetic Plastic Surgery, Los Angeles, California, May 2, 1998.

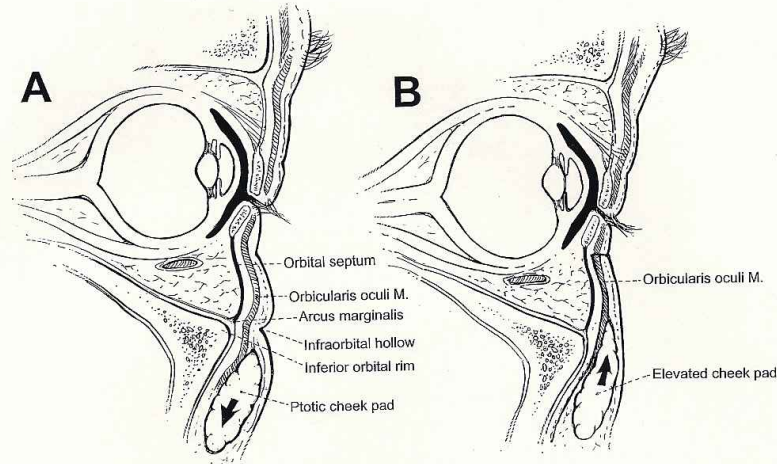


FIG. 1. (Left) A ptotic cheekpad complex characterizes an aging eye. This consists of the ptotic orbicularis oculi muscle, malar fat pad, and associated subcutaneous tissues. Note how the descent of the cheekpad complex leaves the bony infraorbital rim and infraorbital soft tissues exposed and hollow. (Right) The superficial subciliary cheek lift elevates the malar fat pad and cheekpad complex and effaces the nasojugal groove by lifting the cheekpad complex.

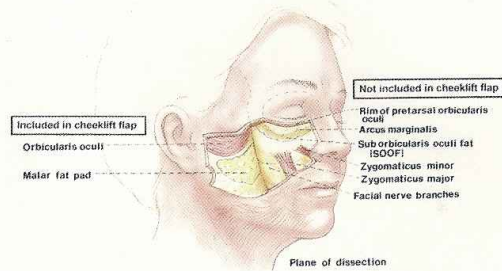


FIG. 2. Only the orbicularis muscle, the malar fat pad, and the cheekpad complex are included in the superficial subciliary cheek lift flap. The pretarsal orbicularis, orbital septum with arcus marginalis, and zygomaticus muscles are left in place.

degree of skin and muscle redundancy is observed. If the patient has had two prior face lifts and has never had a midface correction procedure, he or she is likely to have a significant medial face "curtain" effect. A longer lateral extension will be necessary.

The lateral extension of the subciliary incision is more visible than a conventional lower blepharoplasty subciliary incision because of the more lateral extension. Many younger patients have no crow's feet and only moderate upper midfacial ptosis. In these patients, an extended lateral extension will not be tolerated, nor is it necessary.

#### Pretarsal Orbicularis Preservation

The pretarsal strip of orbicularis oculi muscle is important for lower eyelid closure and support (Fig. 3, above, right). Complete removal of this strip and inclusion in the cheek lift may predispose the patient to lower lid hypotonicity and anterior lamellar scarring and ectropion. Therefore, a healthy 4-mm cuff of orbicularis oculi muscle is left intact. Dissection is carried through the orbicularis muscle. No dissection is done lateral to or below the pretarsal orbicularis fibers to preserve the small facial nerve branches to the pretarsal orbicularis muscle. The 4-mm cuff of pretarsal orbicularis muscle is, therefore, left on the lower eyelid, and the suborbicularis space is entered. The size of the orbicularis cuff can, to some extent, be tailored to aesthetic preference; however, a 3 to 4 mm cuff is a necessary minimum for lower eyelid tonicity. Care must be taken not to disturb the facial nerve branches laterally innervating the orbicularis oculi muscle to avoid postoperative hypotonicity of the lower lid.

#### Optional Fat Resection

Entry into the orbital septum is not performed unless the periorbital fat is grossly herniating. Elevation of the cheek will hide a mild to moderate amount of infraorbital fat protuberance. Hamra's principle of orbital fat preservation is observed, with a preference for an

MIDFACE AND INFRAORBITAL  
REJUVENATION PROCEDURES

Subperiosteal midface techniques involve a subperiosteal dissection underneath the frontal branch of the facial nerve at the level of the zygoma.<sup>3</sup> The pull is from a superolateral direction on the temple skin and lateral canthus, which displaces the lateral canthus superiorly.

The subperiosteal cheek lift, which was popularized recently by Hester et al.,<sup>4,5</sup> involves an extended subciliary dissection. This very innovative technique lifts the cheekpad complex and midface by dissecting at a subperiosteal level and using periosteal relaxing incisions from below to allow the flap to rotate upward. Anchoring is to the inferior orbital rim. The operation is nearly always combined with a canthotomy.

The composite face lift procedure by Hamra<sup>6</sup> involves repositioning of the orbicularis muscle to the orbital rim periosteum as a component of a composite rhytidectomy. It can be combined with a zygorbicular dissection and midface elevation.<sup>7</sup> This operation separates the pretarsal orbicularis muscle and includes it in the flap; subsequent dissection is done inferiorly and eventually below the zygomaticus muscle. This flap is then combined with a subcutaneous face lift dissection from below, above the level of the zygomaticus major muscles. Hamra's innovative work on avoiding the lateral sweep and hollow eye appearance that results from a conventional blepharoplasty and face lift underscores the need for some type of midface and nasojugal groove correction as a part of facial rejuvenation.<sup>8</sup>

The arcus marginalis release technique by Hamra<sup>9</sup> smooths the nasojugal area by distributing the infraorbital fat inferiorly over the nasojugal groove without raising the cheekpad complex after resection of a segment of orbital septum. This procedure emphasizes orbital fat preservation rather than resection. Hamra has subsequently modified this technique to include opening, rather than resecting, the orbital septum.

Owsley's<sup>10</sup> isolated malar fat pad elevation involves elevating the malar fat pad in a superolateral direction during a face lift procedure. McCord et al.<sup>11</sup> describe redraping the orbicularis arc in combination with a lateral canthoplasty with bony fixation to treat lower lid ectropion or to produce midfacial smoothing.

The procedure involves drill hole fixation through the superolateral orbital bony rim to fix the lateral canthus, and it can be combined with spacer implants for middle lamellar deficiencies. Other orbicularis redraping operations have been proposed by Fogli,<sup>12</sup> Hinderer et al.,<sup>13</sup> and Trepsat.<sup>14</sup>

Byrd and Andochick<sup>15</sup> described a multiplanar lift encompassing suborbicularis dissection combined with lateral brow, temporal, and upper face lifting. The Madame Butterfly procedure by Schorr<sup>16</sup> can be used to treat the ectropion and excessive scleral show that can occur after a lower blepharoplasty. The dissection involves lysis of the middle lamellar tethering cicatrix, a level, complete canthotomy of the two limbs of the lateral canthus, and lateral and inferomedial undermining of the cheek tissue at the supraperiosteal level; suborbicularis oculi fat is anchored to the periosteum of the orbital rim at the arcus marginalis.

SUPERFICIAL SUBCILIARY CHEEK LIFT

*Technique*

The superficial subciliary cheek lift is an aesthetic operation that raises the cheekpad complex, including the malar fat pad, redundant orbicularis muscle, and associated subcutaneous tissues (Fig. 1). The dissection is superficial, and no undermining of the zygomaticus muscles or the periosteum is done (Fig. 2). Anchoring the complex to the intermediate temporal fascia relieves the lower eyelid of any responsibility for holding up the cheekpad complex.

*Incision*

Local anesthesia is injected in the subciliary roll, a suborbicularis plane along the bony orbital rim, and into the submalar fat pad plane (Fig. 3, *above, left*). Adequate time is allowed for hemostasis, and an extended subciliary incision is made. The incision is carried out laterally into a crow's foot line approximately 4 to 10 mm lateral to the lateral canthus. The lateral extension is determined by the degree of correction required. This, in turn, is determined by the degree of ptosis of the lateral cheek and the depth of the nasojugal groove. The degree of lateral extension is easily estimated preoperatively. The cheekpad is gently elevated at the lateral canthal level, and the

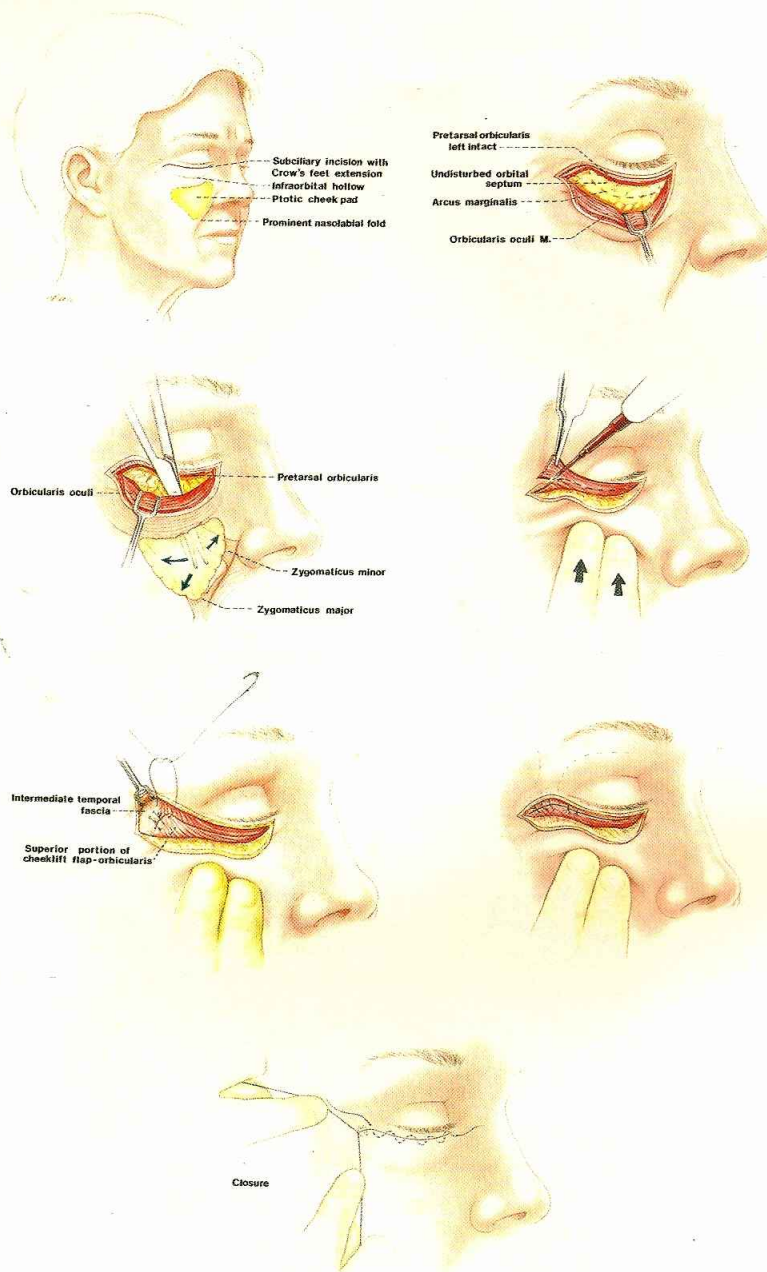


FIG. 3. Stepwise technique for the superficial subciliary cheek lift. (Above, left) Infraorbital aging involves ptosis of the cheekpad complex onto the upper nasolabial fold, which leaves the inferior orbital rim and nasojugal groove exposed. (Above, right) Incision for the superficial subciliary cheek lift leaves pretarsal orbicularis behind. Entry into the orbital septum or arcus marginalis is optional. (Second row, left) Dissection in a suborbicularis, suprazygomatic plane frees the cheekpad complex to move. No underscoring of the periosteum is necessary. (Second row, right) Conservative resection of excess orbicularis and skin is performed. (Third row, left) Attachment of the orbicularis oculi from the cheekpad complex to the intermediate temporal fascia. (Third row, right) Orbicularis muscle is closed as a separate layer in addition to the deep anchoring stitches. (Below) Skin is closed in layers with exact approximation of the lateral incision.

arcus marginalis technique in cases of moderate infraorbital fat excess. This avoids an overly hollow postoperative appearance.

#### *Optional Arcus Marginalis Release*

The medial nasojugal groove is least corrected by the subcutaneous cheek lift operation. If appropriate, release of the medial arcus marginalis, with distribution and securing of medial pocket fat over the medial nasojugal groove, may be performed. The arcus marginalis modification of the lower blepharoplasty can be performed at this time if the nasojugal groove is especially deep; an arcus marginalis release can also be performed concomitantly with the superficial subciliary cheek lift. I use Hamra's modified technique, in which no portion of the orbital septum is excised.<sup>17</sup> Differing slightly from his original description, the orbital septum is simply incised at the arcus marginalis, and the fat is spilled over the bony inferior orbital edge and fixed. This modification may lessen the chance of postoperative middle lamellar retraction with middle lamellar scarring and lid retraction.<sup>16</sup>

#### *Optional Canthoplasty*

It may be necessary, depending on lower lid laxity, to perform a lateral canthoplasty in a traditional fashion, with anchoring to the periosteum of the inferior border of the superolateral inside orbital rim.

#### *Suborbicularis Dissection*

Dissection proceeds inferiorly immediately underneath the orbicularis oculi and malar fat pads (Fig. 3, *second row, left*). A small vessel is frequently present at the center of the lower eyelid dissection at the level of the arcus marginalis/inferior orbital rim. This is subjected to electrocautery. Typically, the extent of dissection is 4 cm inferior and 2 cm lateral to the medial to lateral canthus; however, the extent of dissection is determined by the amount of tension-free upward rotation required. Upward rotation of the cheekpad complex is not tethered by the origin of the zygomaticus muscles because the dissection passes above them. The vector of pull of the cheek lift flap is strictly superior, not lateral or superolateral. This achieves a significant lift directly on the upper nasolabial fold. It accomplishes an anatomic correction of the downward descent of the cheekpad complex that occurs over time.

#### *Skin-Muscle Resection*

Care is taken to be extremely conservative in resecting orbicularis oculi muscle and skin, lest an anterior lamellar deficiency and ectropion or excessive scleral show result (Fig. 3, *second row, right*). At the conclusion of the procedure, the amount of skin-muscle roll underneath the subciliary incision should look slightly excessive to allow for wound contraction. In cases of proptotic eyes, existing ectropion, or post-blepharoplasty round eye deformity, virtually no resection should be performed. In straightforward aesthetic cases with none of the features listed above, surgeons accustomed to subciliary blepharoplasty, in which it is seldom appropriate to resect a significant amount of skin, will be surprised at the amount of infraorbital skin and orbicularis roll that will rotate superiorly and that can be resected.

#### *Flap Rotation and Anchoring*

The superficial subciliary cheek lift relies on fixation of the orbicularis fibers of the cheekpad complex to the coalescence of the deep and superficial layers of the deep temporal fascia (the intermediate temporal fascia) (Fig. 3, *third row, left*). The intermediate temporal fascia is exposed easily by facing the scissors superiorly and spreading, which readily exposes the striated fibers of the intermediate temporal fascia just lateral to the midlateral orbital rim. Fixation must be firm and not subject the lower lid to any tension. Fixation sutures must be well spaced to prevent puckers in the skin and to avoid pulling the flap medially or laterally from the center. Three 5-0 Prolene sutures are typically used to anchor the cheek lift.

#### *Liposuction*

Using a 2-mm cannula, liposuction is performed on the lateral bulge that results from upward rotation of the cheek complex. The lateral eye region should be flat at the conclusion of the procedure.

#### *Closure*

Superficial orbicularis fibers and subcutaneous tissues are closed separately from the deep orbicularis anchoring sutures to ensure flat skin approximation (Fig. 3, *second row, right, and below*).

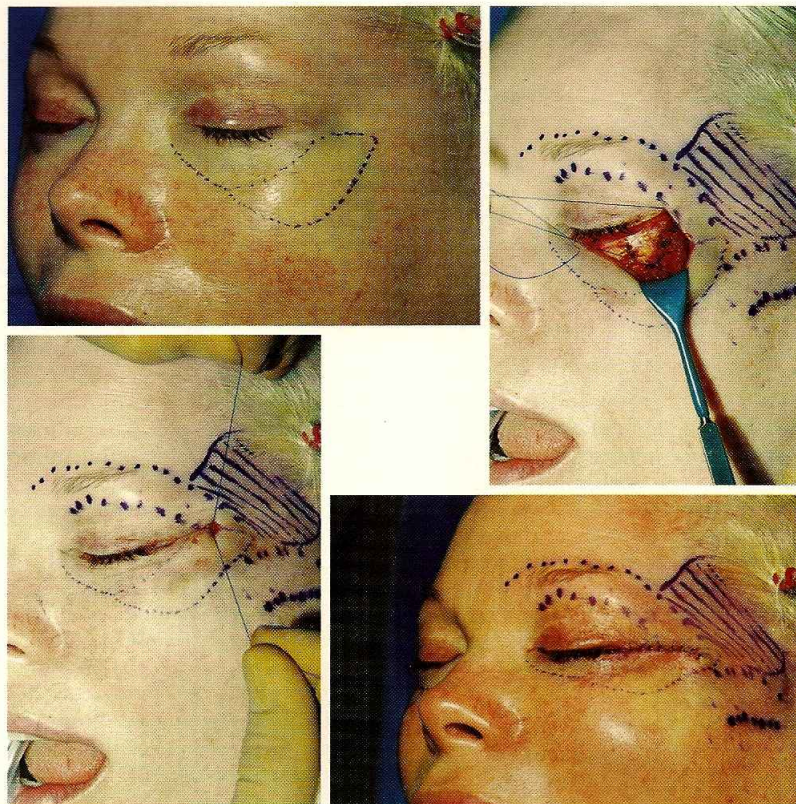

FIG. 4. (Above, left) Preoperative markings after injection of local anesthesia. (Above, right) Extent of undermining and easy mobility of the cheek lift flap. (Below, left) First anchoring stitch from the orbicularis muscle to the intermediate temporal fascia. (Below, right) Postoperative view. Note the region of intermediate temporal fascia (*hatched region*) and zygoma (*outlined*). Comparison of preoperative and postoperative views shows the extent of lift on the cheekpad complex.

#### *Intraoperative Photographs*

The preoperative markings show the preoperative nasojugal groove, extent of undermining, and the deep anchoring stitch (Fig. 4). The amount of rise in the cheekpad complex can be seen by comparing the immediate postoperative photograph with the immediate preoperative photograph in Figure 4.

#### RESULTS

A total of 71 patients underwent bilateral superficial subciliary cheek lift through an extended subciliary incision. Follow-up ranged from 6 months to 3.5 years.

All patients achieved a significant reduction in infraorbital hollowness, cheekpad ptosis, and upper nasolabial fold depth, and an improvement in overall upper midface appearance was accomplished. Typical recovery is sim-

ilar to but slightly longer than that for a conventional subciliary lower blepharoplasty. Results were most noticeable in patients with large infraorbital fat herniations, in whom conventional blepharoplasty typically suffices, and in patients with a hollow infraorbital region and nasojugal groove.

Temporary (less than 2 weeks) mild lower lid hypotonicity was observed in three patients early in the series, presumably due to temporary injury to facial nerve branches to the pretarsal orbicularis. This has subsequently been avoided by not dissecting lateral or deep to the pretarsal orbicularis muscle strip and by excluding (Fig. 3, *above, right*) the pretarsal orbicularis fibers from the cheek lift flap.

Three patients had mild, permanent, increased scleral show. This is now completely avoidable by conservatively resecting tissue

once the cheek lift flap has been secured. Minor scar revisions were necessary in eight patients due to inexact skin approximation, palpability of deep sutures, or excessive fullness at the lateral margin of the incision (dog-ear deformity). These problems have become almost completely preventable with the use of multiple 5-0 Prolene sutures for fixation to the intermediate temporal fascia (rather than a single 4-0 Prolene suture), separate closure of the superficial orbicularis layer and subcutaneous tissues with interrupted sutures, and liposuction with a 2-mm, Mercedes-style liposuction cannula in the lateral extent of the incision.

One complete postoperative internal suture dehiscence requiring revision under local anesthesia occurred in a patient who smoked heavily in the perioperative period and in whom 5-0 polydioxanone sutures were used for fixation rather than 5-0 Prolene sutures.

No long-term drooping, dehiscence, or ptosis of the cheek lift flaps has been observed. No cases of temporary or permanent facial nerve frontal or buccal branch injury were noted. No incidence of numbness indicative of infraorbital branch injury has been observed. In all cases in which the superficial subciliary cheek lift was performed, the correction achieved by 4 weeks postoperatively has been maintained, without any observable downward drift of the cheeks over time. Aesthetic results have been maintained through the duration of this study. The midfacial rejuvenation and nasojugal hollow effacement has been long-lasting and has not recurred.

#### DISCUSSION

Some younger patients have infraorbital hollowness and a prominent nasojugal groove.

When no excess infraorbital fat exists and no canthal tightening must be performed, correcting this deformity is a challenge with a traditional subciliary blepharoplasty with canthoplasty. The superficial subciliary cheek lift provides reliable correction (Fig. 5).

Many older patients have had multiple previous facial rejuvenation surgeries without infraorbital or midface correction. When severe, a midfacial sweep or hanging curtain effect results. Traditional blepharoplasty with canthoplasty can do little to restore the youthful infraorbital look or replace the lost fat. In such cases, a superficial subciliary cheek lift can provide reliable improvement (Fig. 6).

With patients having their first face lift, the surgeon should consider complete rejuvenation of the infraorbital region if cheekpad ptosis and a prominent nasojugal groove are present. Observed critically, most patients requiring facial rejuvenation have some degree of infraorbital hollowness, cheek ptosis, and a prominent nasojugal groove, independent of herniating infraorbital fat. In these patients, a harmonious rejuvenation can be achieved more reliably when the infraorbital and upper midfacial tissues are elevated (Fig. 7).

The superficial subciliary cheek lift may offer advantages over other midface techniques. No subperiosteal dissection is necessary, because the dissection undermines only the very pliable skin-muscle-malar fat pad complex, not the unyielding periosteum. Scoring the periosteum from below to allow superior mobilization of the cheek lift flap is not necessary. The swelling attendant with a subperiosteal dissection does not occur; rather, minimal postoperative swelling occurs with this more superficial technique, which resembles a conventional lower

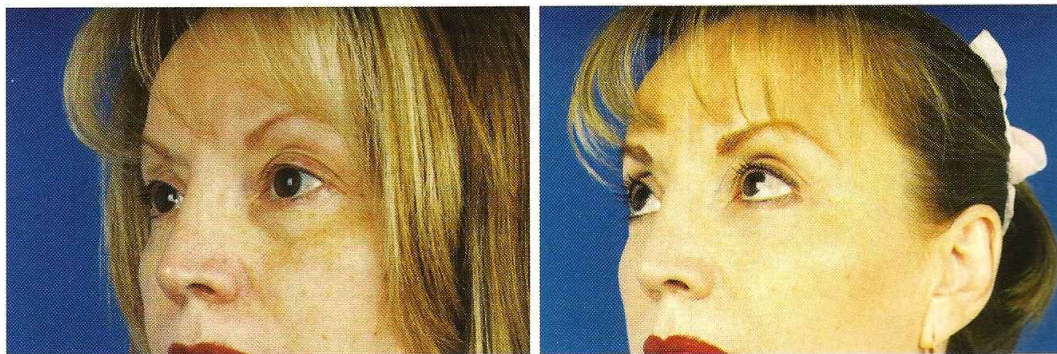

FIG. 5. (Left) A 42-year-old woman with infraorbital hollowness and no excess infraorbital fat. (Right) Six months after superficial subciliary cheek lift.

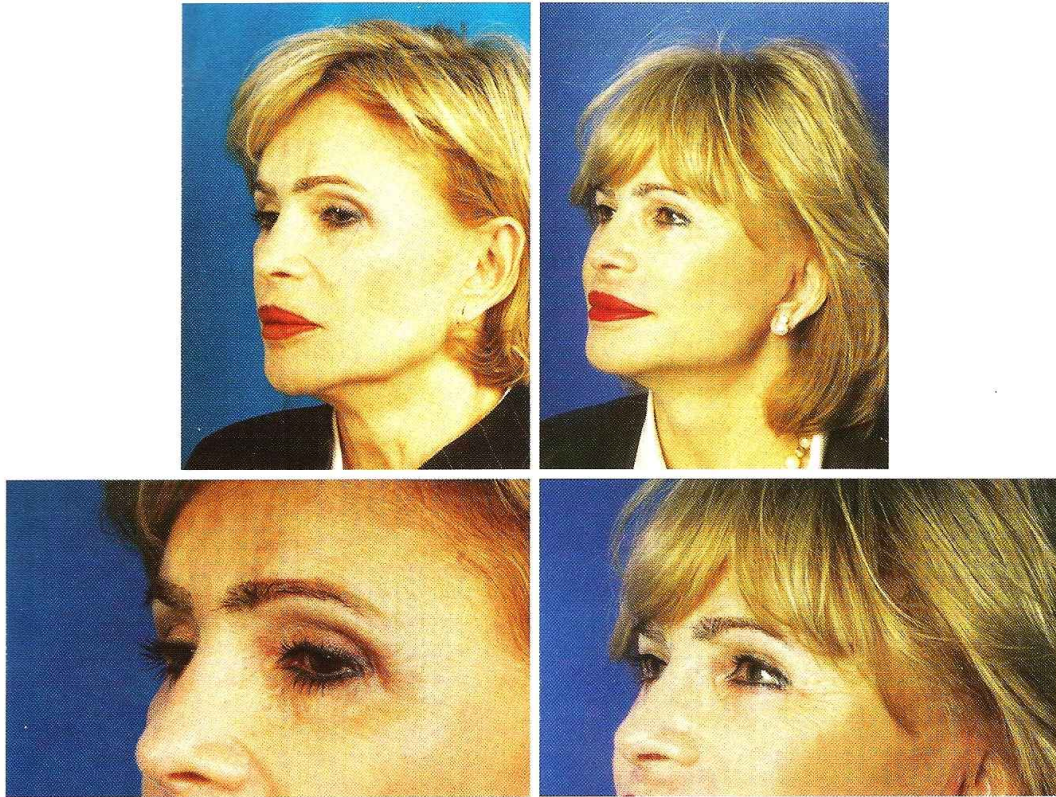

FIG. 6. (Left) A 63-year-old woman after three previous face-lifting techniques. Note the ptotic midface and hollow infraorbital region. (Right) Postoperative view after 8 months shows correction of infraorbital and nasojugal hollowness.

blepharoplasty. Additionally, the purchase of the cheek lift flap is above the level of the lateral canthus, which allows better purchase and a higher lever arm than with infraorbital periosteal fixation. I find that less postoperative scleral show and less ectropion occur with the superficial subciliary cheek lift than with subperiosteal techniques. Because no dissection is performed around facial nerve branches (including the frontal branch, as with endoscopic techniques), the chance of facial nerve injury is virtually nil. No dissection is necessary around the infraorbital nerve trunk, as with a subperiosteal technique, which reduces the chance of numbness if this nerve is subjected to traction or injury. It is not necessary to perform a concomitant face lift with this procedure, as with biplanar techniques; the superficial subciliary cheek lift can be performed alone or in combination with a face lift. Unlike biplanar midface techniques, the superficial subciliary cheek lift deliberately leaves a cuff of

pretarsal orbicularis intact, with its nerve and blood supply. I think this helps prevent postoperative lower lid hypotonicity. Deliberate anchoring sutures to the intermediate temporal fascia provide a secure anchor for the cheek lift flap and are crucial to this technique. They also allow the superficial subciliary cheek lift to be performed alone or in conjunction with a face lift.

Younger patients desiring neck and jawline rejuvenation frequently can benefit from infraorbital rejuvenation as well, which gives the patient a more comprehensively rejuvenated appearance (Fig. 8). A patient who has had even a single face lift without infraorbital or midface correction may present with a gaunt, "done" appearance. It is tempting to leave the lower eyes alone when considering further rejuvenation. Yet, this done appearance can often be reversed with a superficial subciliary cheek lift (Fig. 9).

Patients who present with prominent in-



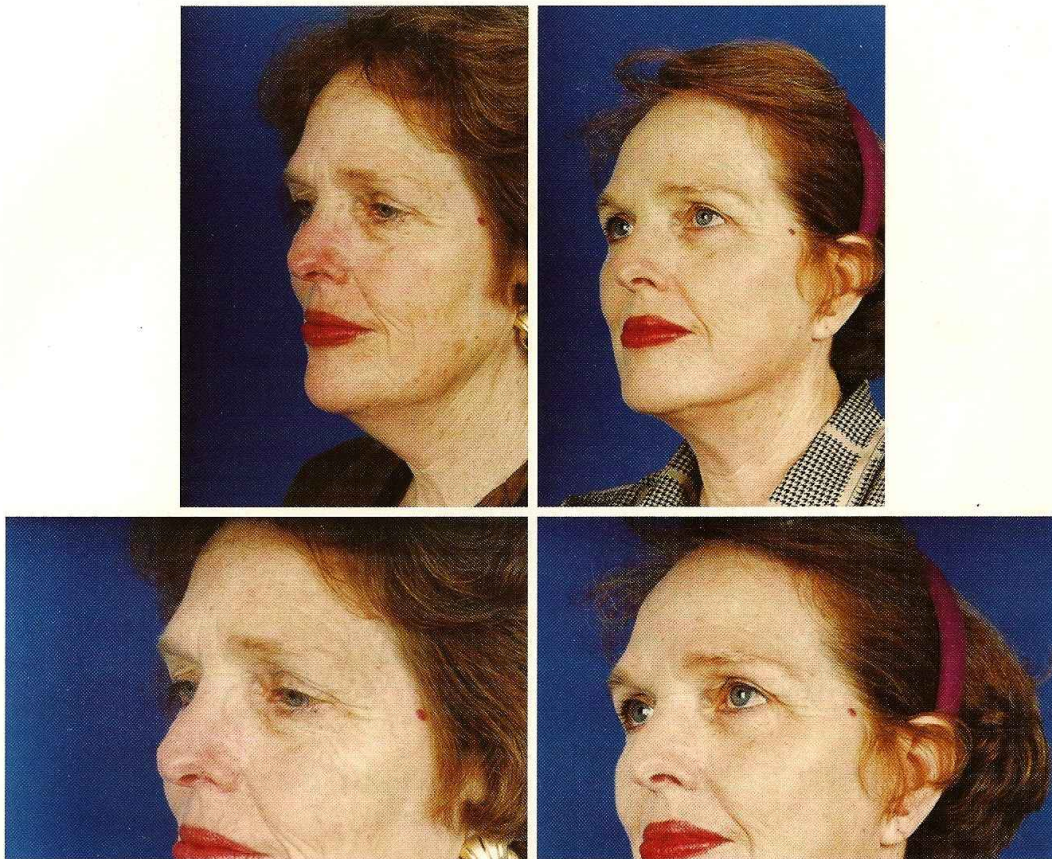


FIG. 7. (Left) A 67-year-old woman with facial and infraorbital aging. (Right) Postoperative view 1 year after face lift, upper blepharoplasty, and superficial subciliary cheek lift.

fraorbital fat herniations and a deep nasojugal groove can benefit from very limited resection of the infraorbital fat combined with a superficial subciliary cheek lift. A traditional lower blepharoplasty might leave such a patient looking hollow rather than smoothly rejuvenated (Fig. 10).

The patient with a very low nasojugal groove and no infraorbital fat herniations presents a particular problem. Excess skin resection would almost certainly result in postblepharoplasty round eye deformity or frank ectropion. Such patients benefit greatly from a superficial subciliary cheek lift (Fig. 11).

#### CONCLUSIONS

Several aesthetic conditions challenge or exceed the capacity of traditional subciliary blepharoplasty with canthoplasty to correct, because of the very weak lower eyelid. These

include the prominent nasojugal groove, infraorbital hollowness and, especially, postblepharoplasty infraorbital hollowness. In such cases, the superficial subciliary cheek lift can elevate and fixate the ptotic cheekpad complex and efface the infraorbital hollow appearance that can characterize traditional subciliary or transconjunctival (with or without laser resurfacing) rejuvenations.

The subcutaneous cheek lift is a technically straightforward aesthetic technique for lifting and fixing the tissues of the nasojugal and infraorbital region through an extended subciliary incision. The principle of orbital fat preservation, rather than routine resection, is observed. Anchoring the cheekpad complex to the intermediate temporal fascia avoids traction to the lower eyelid and allows high purchase for lifting the cheekpad complex.

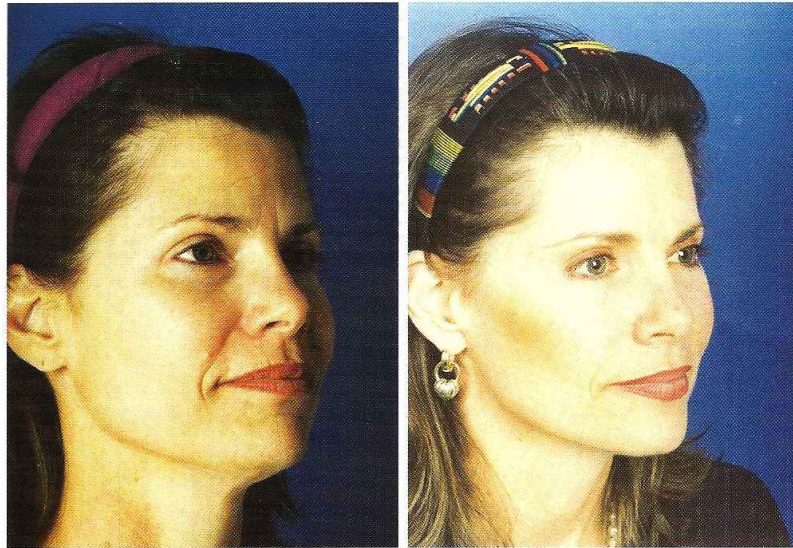

FIG. 8. (*Left*) A 42-year-old woman with facial laxity and infraorbital hollowness. (*Right*) Postoperative view 16 months after face lift and superficial subciliary cheek lift.

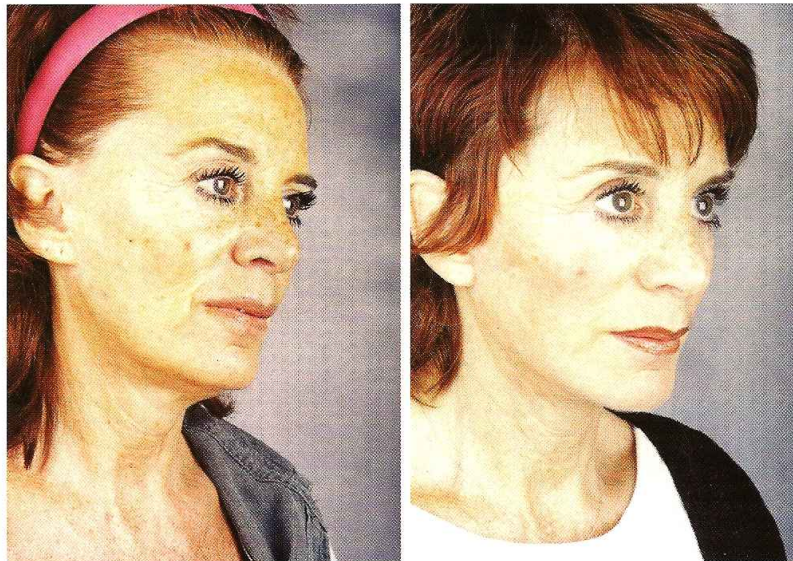

FIG. 9. (*Left*) A 50-year-old woman with previous face lift and blepharoplasty procedure with infraorbital hollowness. (*Right*) Postoperative view 1 year after revision face lift and superficial subciliary cheek lift.

The superficial subciliary technique offers inherent safety in terms of frontal branch and infraorbital nerve injury. Recovery is rapid because subperiosteal dissection is avoided. Purchase is from a superior direction at the intermediate temporal fascia, rather than to the infraorbital rim. No canthotomy or drill fixa-

tion is required, facilitating the ease of the operation.

The superficial subciliary cheek lift safely rejuvenates the nasojugal groove, upper nasolabial fold, and infraorbital region. The procedure does not require drill holes, endoscopic equipment, or a canthotomy. The technique is

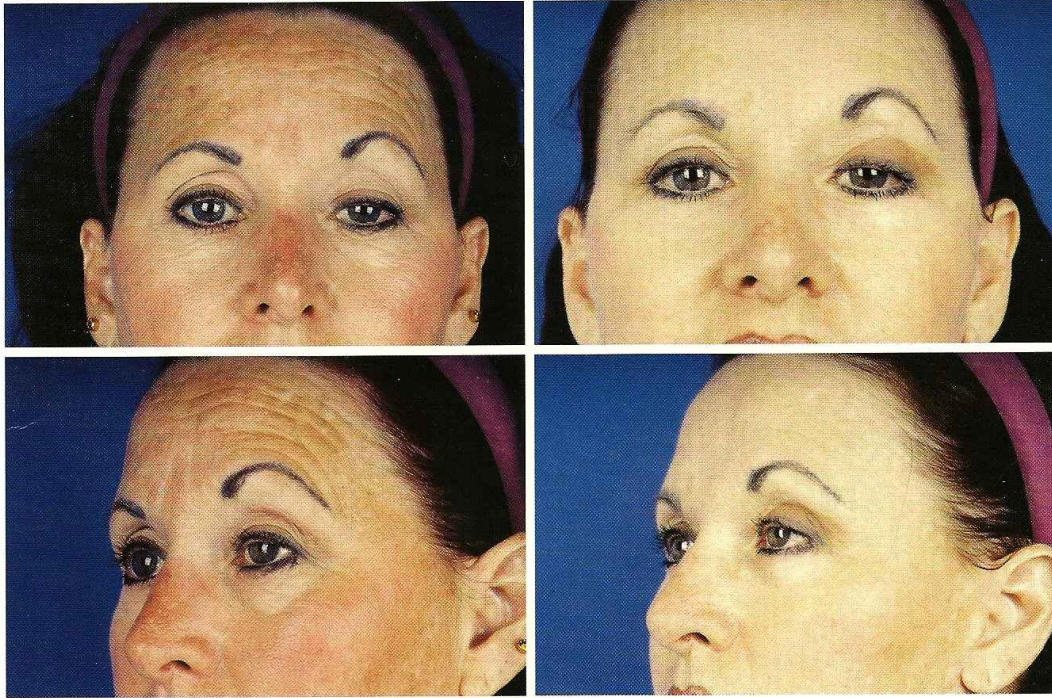

FIG. 10. (Left) A 53-year-old woman with facial laxity, prominent nasojugal groove, and infraorbital hollowness. (Right) Postoperative view 18 months after face lift and superficial subciliary cheek lift.

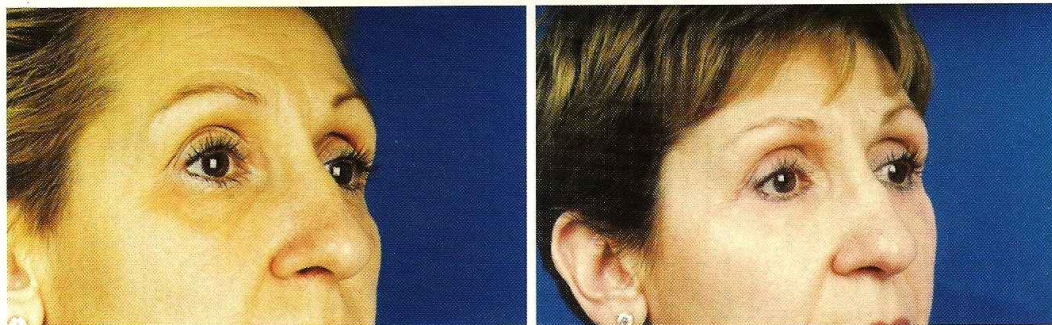

FIG. 11. (Left) A 52-year-old woman with prominent infraorbital hollowness, prominent nasojugal groove, and no infraorbital excess. (Right) Postoperative view 10 months after superficial subciliary cheek lift.

technically straightforward and reproducible, and recovery is rapid. The complication rate is inherently low. This technique was intended for use by surgeons who have formal training in surgery of the face, ectropion repair, facial nerve anatomy, and principles of musculocutaneous flaps. The superficial subciliary cheek lift is a useful adjunct to traditional subciliary blepharoplasty in patients who also have nasojugal hollowness and ptosis of the cheekpad complex.

*Brent R. Moelleken, M.D.  
120 S. Spalding Drive # 340  
Beverly Hills, Calif. 90210  
drbrent@drbrent.com*

**CAUTION**

The author cautions surgeons performing this technique to exercise conservatism in their initial series of cases. Performing the superficial subciliary cheek lift on patients who have

proptosis or have had previous blepharoplasty increases the complexity of the operation and is recommended only after achieving familiarity with first-time cases.

## REFERENCES

1. Moelleken, B. R. W. The Subcutaneous Cheeklift. In *Proceedings of the California Society of Plastic Surgeons*, Santa Barbara, Calif., March 14, 1998.
2. Moelleken B. R. W. The Subcutaneous Cheeklift. In *Proceedings of the American Society for Aesthetic Plastic Surgery*, Los Angeles, Calif., May 2, 1998.
3. Ramirez, O. M. Endoscopic forehead and face-lift: Step by step. *Oper. Tech. Plast. Reconstr. Surg.* 2: 129, 1995.
4. Hester, T. R., Codner, M. A., and McCord, C. D. The inferior retinacular lateral canthoplasty: A new technique (Discussion). *Plast. Reconstr. Surg.* 100: 1271, 1997.
5. Hester, T. R., Codner, M. A., and McCord, C. D. The centropacial approach for correction of facial aging using the transblepharoplasty subperiosteal cheek lift. *Aesthetic Surg. Q.* 16: 51, 1996.
6. Hamra, S. T. Composite rhytidectomy. *Plast. Reconstr. Surg.* 90: 1, 1992.
7. Hamra, S. T. The zygorbicular dissection in composite rhytidectomy: An ideal midface plane. *Plast. Reconstr. Surg.* 102: 1646, 1998.
8. Hamra, S. T. Frequent face lift sequelae: Hollow eyes and the lateral sweep: Cause and repair. *Plast. Reconstr. Surg.* 102: 1658, 1998.
9. Hamra, S. T. Arcus marginalis release and orbital fat preservation in midface rejuvenation. *Plast. Reconstr. Surg.* 96: 354, 1995.
10. Owsley, J. Q. Lifting the malar fat pad for correction of prominent nasolabial folds. *Plast. Reconstr. Surg.* 91: 463, 1993.
11. McCord, C. D., Jr., Codner, M. A., and Hester, T. R. Redraping the inferior orbicularis arc. *Plast. Reconstr. Surg.* 102: 2471, 1998.
12. Fogli, A. L. Orbicularis muscleplasty and face lift: A better orbital contour. *Plast. Reconstr. Surg.* 96: 1560, 1995.
13. Hinderer, U. T., Urriolagoita, F., and Vildosola, R. The blepharo-periorbitoplasty: Anatomical basis. *Ann. Plast. Surg.* 18: 437, 1987.
14. Trepsat, F. Facelift of the malar, jugal and nasolabial regions. *Ann. Chir. Plast. Esthet.* 39: 597, 1994.
15. Byrd, H. S., and Andochick, S. E. The deep temporal lift: A multiplanar, lateral brow, temporal and upper face lift. *Plast. Reconstr. Surg.* 97: 928, 1996.
16. Shorr, N. Madame butterfly procedure with hard palate graft: Management of postblepharoplasty round eye and scleral show. *Facial Plast. Surg.* 10: 90, 1994.
17. Hamra, S. T. The zygorbicular dissection in composite rhytidectomy: An ideal midface plane. *Plast. Reconstr. Surg.* 102: 1646, 1998.